

UP-DATE OF INTERPOSITION ARTHROPLASTIES OF THE SMALL JOINTS IN AN EXPERIMENTAL MINI PIG MODEL

E. Waris¹, N. Ashammakhi², M. Lehtimäki³, R.-M. Tulamo⁴, M. Kellomäki⁵, P. Törmälä⁵, R. Lappalainen⁶, S. Santavirta⁷, Y.T. Konttinen¹

¹ Institute of Biomedicine/ Anatomy, Biomedicum Helsinki, University of Helsinki, Finland; ² Division of Plastic Surgery, Department of Surgery, Oulu University Hospital; ³ Department of Rheumatoid Surgery and Orthopedics, Tampere University Hospital; ⁴ Department of Clinical Veterinary Sciences, Faculty of Veterinary Medicine, University of Helsinki; ⁵ Institute of Biomaterials, Tampere University of Technology; ⁶ Department of Applied Physics, Kuopio University; ⁷ Department of Orthopaedics and Traumatology, Helsinki University Central Hospital.

Silicone interposition arthroplasty is the most commonly used method for reconstruction of metacarpophalangeal (MCP) joints. Swanson silicone arthroplasty restores hand function in appropriately selected patients. However, decreased mobility, recurrent pain and instability become prevalent with long-term follow-up. Reported complications include infection, implant dislocation and fracture [1]. The lack of bone stock may cause a formidable challenge in revision arthroplasty.

Modern tissue engineering technology has led to the development of bioabsorbable scaffolds for reconstruction of small joints of the hand [2]. This experimental study is undertaken to evaluate biological behavior, bioabsorption and biocompatibility of bioconstructive and Swanson silicone interposition arthroplasties performed in the MCP joints of minipigs using histological, microradiographic, radiographic and range of joint motion (ROM) analyses.

Materials and Methods.

A cylindrical scaffold made of poly-L/D-lactide (L,D-monomer ratio of 96/4, P(L/D)LA 96/4) was used in this study. Raw P(L/D)LA 96/4 (Purac biochem B.V. Gorinchem, Netherlands) was melt-spun into a 4-ply multifilament, knitted to tubular jersey and then rolled to a cylindrical scaffold Ø8 x 3.5 mm in size. The silicone Swanson finger joint implant (Wright Medical Technology, Inc.) of size 00 was appropriate to meet the anatomical requirements.

12 skeletally mature female minipigs were operated. The operation was performed on both fore hooves under tourniquet control in general anaesthesia. After the joint was exposed, the metacarpal head and the base of proximal phalanx were resected, removing all cartilage to simulate end-stage rheumatoid arthritis. The joint reconstruction was achieved either with P(L/D)LA 96/4 scaffold, or a Swanson silicone implant. Resection without any implantation serves as the third study group.

The animals are sacrificed at 12 and 26 weeks as well as at 1 and 3 years to obtain three specimens from each study group. The bone specimens are fixed in a series of ethanol immersions of rising concentrations and embedded in methylmetacrylate. For histological microradiographic and OTC-fluorescence studies, longitudinal sections are cut with a microtome. The axillary lymph nodes are evacuated, and also biopsies of the liver and spleen are performed to demonstrate histologically possible lymphadenopathy and silicone granulomas.

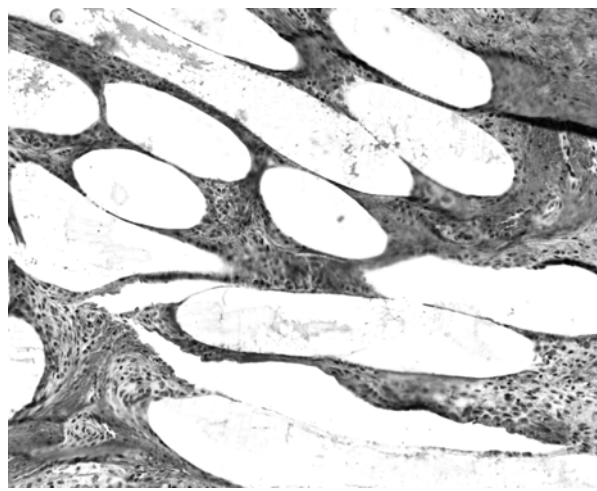
Result and Discussion.

All minipigs have been operated in autumn 2001. Cylindrical P(L/D)LA 96/4 implant serves as a scaffold for fibrous cell invasion. Histological observations revealed that the porous structure of the scaffold was totally invaded by fibrous tissue by. The biocompatibility was good, and no adverse cellular reactions to the polymer were noted. Swanson silicone implants were surrounded by fibrous capsule. Silicone wear particles and numerous reactive cells were seen in the tissue-silicone interface. Silicone particles were also detected in the regional axillary lymph nodes indicating particle migration by ESEM and FTIRI.

The animals are followed up to three years when the P(L/D)LA 96/4 scaffold should be completely absorbed and replaced by the animals own tissue. The bioconstructive P(L/D)LA 96/4 scaffold provides apparently a resilient, functional MCP arthroplasty allowing unlimited use of the joint and avoiding long-term complications and restrictions of current biostable interposition implants.

References.

- [1] Vasenius J et al. *Current Orthopaedics* 14, 284-289, 2000;
- [2] Lehto MUK, Lehtimäki, MY, Paasimaa S, Törmälä, P: PCT Pat. Appl. No. FI96/00035; [3] Honkanen P et al. *Biodegradable PLDLA scaffold prosthesis in the MCP-arthroplasty of rheumatoid patients. SOT* 2, 23, 111, 2000



Photomicrograph of P(L/D)LA 96/4 scaffold at 10 weeks, Masson-Goldner trichrome