
Nordic Orthopedic Federation

Sessions	Page	Abstracts
Polytrauma	1	1-6
Hip arthroplasty	3	7-13
Whiplash	6	14-17
Hip arthroplasty	8	18-24
Spine and free papers	11	25-32
Fractures and traumatology	15	33-38
Cervical spine	17	39-43
Knee arthroplasty	19	44-48
Childrens fracture and orthopedics	21	49-52
Basic research	23	53-58
Spine	25	59-64
Childrens fracture and orthopedics	28	65-67
Hip fracture	30	68-75
Upper extremity	32	76-80
Primary and revision arthroplasty	35	81-86
Free papers	37	87-94
Hip revision	40	95-99
Sports and foot	42	100-106
Posters	45	P1-P21

Suppl. 280, Vol. 69, No. 3, 1998

SCANDINAVIAN UNIVERSITY PRESS



Oslo - Copenhagen - Stockholm - Boston

49th Congress of the Nordic Orthopedic Federation

Copenhagen, Denmark, June 3–6, 1998

Editor: Thomas Kiær

Department of Orthopedics
Copenhagen University Hospital
Blegdamsvej 9
DK-2100 København, Denmark

Session 1: Polytrauma

1. Treatment of complex calcaneal fractures with bony defects from landmine blast injuries with circular external fixator

Sabri Atesalp, Mustafa Basbozkurt, Ethem Gür, Ercan Köseoglu

Dept. of Orthopaedics and Traumatology, Gülhane Military Medical Academy and Faculty, 06018, Ankara, Turkey

18 severely comminuted calcaneal fractures with bone loss defects and 4 massive calcaneal destruction as a result of landmine blast injury were treated with circular external fixator by distraction osteogenesis for calcaneal reconstruction. One case of bilateral calcaneal injury with bone loss defect is also included.

The definitive orthopaedic treatment was delayed between 3 and 28 months with an average delay of 10 months after the landmine blast injury. This was due to the severe tissue destruction needed to be treated following the injury. The time from the beginning of circular external fixator use until the removal of the apparatus ranged between 110 and 175 days with an average of 144 days. The mean follow up for the cases was 18 months. Of the 22 calcaneal injury, there were 4 excellent, 11 good, 5 fair, and 2 poor results observed. The study showed that better results were achieved in cases with less bony defect and whose definitive orthopaedic treatment following injury was delayed for soft tissue problems.

2. Disturbed consolidation of femoral shaft fractures treated by intramedullary nailing

Harri Pihlajamäki, Sari Salminen, Lea Pulliainen and Ole Böstman

Dept. of Orthopaedics and Traumatology, Helsinki University Hospital, Helsinki, Finland

The aim of this study was to scrutinize the factors that predispose a femoral shaft fracture to disturbed consolidation after intramedullary nailing and to analyze the effectiveness

of different operative methods in the treatment of the disorder.

Patients and methods: During a 7-year period a total of 278 patients aged 15 years or more with 280 fresh femoral shaft fractures were treated at the authors' department by using intramedullary nailing. The mean age of the patients at the time of the injury was 36 (15-88) years. Failed consolidation was defined as a disturbed process of union that probably would not proceed to solid healing of the fracture without active surgical measures.

Results: Among 280 femoral shaft fractures in 278 adult patients failed consolidation was observed in 36 (13%) cases. At least one predisposing factor could be identified in 32 of the 35 patients with 36 fractures showing failure of consolidation. There were 11 comminuted Winquist-Hansen grade-III fractures and 8 grade-IV fractures. There were 9 open fractures. In 9 cases an iatrogenic additional comminution of the fracture occurred during the primary nailing procedure. In 9 cases the fracture site was opened for reduction during the initial intramedullary nailing procedure. In order to achieve solid union, one later reoperation for the failed consolidation was sufficient in 24 patients, but 7 were operated twice and 5 three times. The unsuccessful operations were autogenous bone grafting in 5 cases, dynamization alone in 4 cases, exchange nailing in one case and exchange nailing with autogenous bone grafting in one case.

Conclusions: Primarily or iatrogenically severely comminuted fracture, fractures with severe soft tissue injury and patients who had the fracture site opened during the nailing procedure should be closely monitored to identify signs of failure of consolidation. Exchange nailing seems to be the most effective method for the treatment of disturbed union process. Autogenous bone grafting alone is not a sufficient method for treatment of femoral shaft non-union.

3. Epidemiological features of femoral shaft fractures

Sari Salminen, Harri Pihlajamäki, Veikko Avikainen¹, Ole Böstman

Dept. of Orthopedics and Traumatology, Helsinki University Central Hospital, Helsinki and ¹Dept. of Surgery, Central Hospital of Central Finland, Jyväskylä, Finland

We performed an epidemiological and morphological analysis of 201 femoral shaft fractures in 192 consecutive skeletally mature patients in a semi-urban county over a 10-year period. The overall incidence was 9.5 fractures per 10⁵ person-years. The highest age- and gender-specific incidences were encountered in men from 15 to 24 years of age and in women aged 75 years or more, the values being 39 and 21 per 10⁵ person-years, respectively. 151 (75%) fractures were the result of a high-energy trauma, 131 of which occurred in road-traffic accidents. But, unexpectedly, there were 50 low-energy fractures. Fractures of the middle third of the diaphysis comprised 79% of all cases. Using biomechanical classification, the majority 155 (77%) of the fractures were transverse, oblique or oblique-transverse. As regards the degree of comminution, the Winquist-Hansen grade-0 (non-comminuted) fracture was the most common. There were 48% AO type A, 39% type B₁ and 13% type C fractures. Only 7 of the 27 possible AO subgroups occurred with a frequency of at least 3.7%. In 93 (46%) of the fractures, the angle between a line perpendicular to the long axis of the femur and the main fracture line was less than 30°. Of the 25 open fractures, 14 were of Gustilo type-II. All 6 type-III open injuries were of type IIIa.

The great number of transverse fractures with minimal comminution in the mid-femur, suitable for conventional nailing, indicates that the need for interlocking nailing in femoral shaft fractures should not be overestimated. Preventive measures should be focused on protection of car drivers, especially young men, and to effective treatment of osteoporosis in elderly women.

5. Treatment of open pelvic fractures

Olav Røise, Andreas Runge and Stein Øvre

Department of Orthopaedics, Ullevaal University Hospital, Oslo, Norway

Open pelvic ring disruption represents a serious clinical problem with a mortality rate up to approximately 40–50%. This alarmingly high rate of deaths is partly related to uncontrollable haemorrhage and partly related to severe associated injuries. In this report we have evaluated the treatment of open pelvic fractures at our institution.

Material and methods: Patients with open pelvic fractures have since 1995 been registered prospectively. This study is, however, based on partly retrospective and partly prospective collection of patient data. All patients have been followed after hospital discharge by the first author.

From 95 we have treated 11 patients with open pelvic fractures. Mean age was 28 (range; 8–61) and mean Injury Severity Score was 30 (9–59). Four patients were admitted directly to our center from the scene of accident, whereas 7 were transferred early after the accident from local hospitals.

Associated injuries were seen 9 patients (82%); anorectal (2), intestinal perforation (2), diaphragmatic rupture (1), spleen rupture (1) urogenital (5), vascular (5), nerve (3), other skeletal (7) and head (1).

Four patients had vertical unstable type C fractures (three treated with internal fixation and one with external frame), four had vertical stable, but rotational unstable type B fractures (one with open book (B1) was treated with internal fixation and one was treated with external frame, whereas one with lateral compression injury (B2) was treated with external frame and one conservatively), two patients had stable type A fractures (treated conservatively) and one had a T-type acetabular fracture (treated with internal fixation). Three of the pelvic fractures involved acetabulum.

Two patients with anorectal injury, three patients with perineal skin wounds/laceration and one with a skin cut at the iliac crest were treated with colostomy.

Results: Mean stay in the Intensive Care Unit was 13 (1–32) days. Three patients had sepsis. None of the patients had ARDS. In three patients deep infection developed, but all resolved after local surgical revision and antibiotics. All patients survived. One is totally disabled due to head injury. All fractures healed without secondary orthopaedic procedures.

Conclusion: Patients with open pelvic fractures have potential lethal injuries which necessitates an aggressive attitude both in early resuscitation and in the early follow up. Compared to other reports our results are surprisingly good. Based on our own experience we advocate early colostomy in patients with anorectal and/or perianal injuries. Internal fixation of highly unstable fractures might be favourable in these patients, though no certain conclusions can be drawn due to too small number of patients.

6. Admission level of Gc-globulin predicts outcome after multiple trauma

Benny Dahl, Frank V Schiødt, Peter Ott, Michael Nielsen and Thomas Kier

Dept. of Orthopaedics and Dept. of Hepatology, Rigshospitalet, Denmark

Experimental data suggest that the release of excessive amounts of actin into the circulation, may result in a condition resembling multiple organ failure. The plasma protein Gc-globulin is responsible for clearance of actin from the circulation. It has previously been demonstrated, that the serum level of Gc-globulin is reduced after multiple trauma. The purpose of this study was to determine, if admission levels of Gc-globulin can predict survival after multiple trauma.

Material and methods: 57 consecutive patients with a median Injury Severity Score of 18 (16–75) were included. All

patients had a blood sample taken median 42 (19–110) minutes after the injury. All patients were scored with the TRISS-Like score, predicting probability of survival. A Receiver Operating Characteristic curve was used to determine the optimal cut-off value of Gc-globulin in prediction of survival. Mann-Whitney test was used for comparison between groups.

Results: All patients had significantly reduced levels of Gc-globulin compared to normal controls ($p < 0.05$). 16 patients died and 41 patients survived. The admission level of Gc-globulin was significantly higher in the group of survivors compared to non-survivors. Median 237 mg/L vs. 188 mg/L ($p < 0.01$). The predictive ability of Gc-globulin regarding survival was comparable with that of the TRISS-Like score.

Conclusion: The results of this study could mean that Gc-globulin, in combination with other parameters, may serve a routine tool for early identification of patients at risk after severe injury.

Session 2: Hip arthroplasty

7. Treatment of pathological fractures of the proximal femur by cemented hemiarthroplasty

PDS Dijkstra¹, T Wiggers², H Boxma³

Department Orthopaedic Surgery, Westeinde hospital, Den Haag¹, Surgical Oncology, Daniel Den Hoed Cancer Center, Rotterdam², Surgery, Zuiderhospital, Rotterdam³, The Netherlands

The incidence of bone metastases in the long bones increases due prolonged survival as a result of more effective treatment of the primary tumours. In 10% an actual fracture of the proximal femur occurred in patients with skeletal metastases of mamma carcinoma.

A retrospective analysis of painrelief, mobilisation, complications after surgery for pathological fractures of the proximal femur due to bone metastases in 50 patients were studied. Breast carcinoma was the primary tumor in the majority of the patients. These patients with 52 fractures, 40 actual and 12 impending, were treated with cemented hemiarthroplasty.

Painrelief was achieved in 90% of the patients. Fourthly four patients (85%) were able to walk in 7 days postoperatively. In ten patients a systemic complication occurred. There was one local complication. In 6 cases the endoprosthesis failed; luxation, refracture ($n=2$) and loosening ($n=2$). The patient survival rate was 55% after six months.

In conclusion, despite the poor life expectancy, our results show that cemented hemiarthroplasty for the treatment of pathologic fractures due to bone metastases is a safe method to improve quality of life.

8. Uncemented acetabular components vs Charnley cups—mid-term results from the Norwegian Arthroplasty Register

Leif Ivar Havelin, Lars B Engesaeter

Dept. of Orthopaedic Surgery, Haukeland University Hospital, Bergen, Norway

It is a common belief that primary uncemented acetabular components perform better than cemented cups, in young patients. We have compared the results of uncemented cups with those of cemented Charnley cups in different age groups.

Material and methods: We assessed the results of all primary uncemented acetabular components that had been inserted in Norway after 1987 ($n=7150$). As control we used primary Charnley cups cemented with high viscosity cement ($n=18940$). The uncemented cups were grouped after design properties. The comparison was done separately in different age groups (<50, 50–60, 60–70, and >70 years). The groups were similar concerning gender and diagnosis. Survival analyses by the Kaplan-Meier method were performed with revision of the cup for any reason as end-point.

Results: Non of the uncemented groups had better results than the Charnley cups in any age group. The uncoated threaded cups were inferior to all other designs in all age groups. In the total material, the probability for survival at 8 years for the HA-coated cups (n=3642) was 93 % (95% CI 90-96), for the Charnley cups: 96.9% (95% CI 96.7-97.1), for the porous-coated hemispheric cups (n=1589) 94% (95% CI 90-97), and for the threaded uncoated cups (n=1919) 83% (95% CI 80-85). Within all groups there were statistically significant differences among the cup brands. Aseptic loosening was the dominating reason for revisions of the Charnley cups, whereas wear, dislocation, and osteolysis were more common reasons for the uncemented cups.

Conclusion: We were not able to document better mid-term results for uncemented cups than cemented cups in any age group.

9. The duration of systemic antibiotic prophylaxis in primary THR—a study from the Norwegian Arthroplasty Register

Lars B. Engesaeter¹, Stein Atle Lie^{1,2} Birgitte Espehaug^{1,2} and Leif I Havelin¹

¹Department of Orthopaedics, Haukeland University Hospital, ²Devison for Medical Statistics, University of Bergen, Bergen, Norway

In a recent study from the Norwegian Arthroplasty Register on cemented primary total hip replacements it was demonstrated that systemic antibiotic prophylaxis combined with antibiotic-containing bone cement, reduces the risk for revision of THR compared to other prophylaxis regimens. In this study we have focused on the effect of the duration of the systemic antibiotic prophylaxis on the risk for revision.

Patients and methods: For the present analysis we selected THR operated because of osteoarthritis during 1987–1996 with the Charnley prosthesis with gentamycin-containing high-viscosity cement and with systemic antibiotic prophylaxis with either a cephalosporin (cephalotin or cefuroxime) or a beta-laktamase resistant penicillin (cloxacillin or dicloxacillin). Multivariate Cox analysis was performed with adjustment for the influence of gender and age.

Results: 6,115 THR fulfilled the inclusion criteria. The systemic antibiotic was cephalosporin in 70% and penicillin in 30%. The duration of the prophylaxis was 1 day in 52%, 2 days in 17% and 3 days in 18%. The over-all Kaplan-Meier 7 year revision percentage was 4.2% with no differences for 1, 2 or 3 days systemic antibiotic prophylaxis (p=1.00). Neither could any effects be demonstrated of the duration of the prophylaxis on the revision rates for aseptic loosening (3.5%)(p=0.70) or for infection (0.5%)(p=0.77).

Conclusions: Results from the Norwegian Arthroplasty Register shows that systemic antibiotic prophylaxis beyond the day of the operation will not give any further reduction in the risk for revision of a primary THR.

10. Hip disease and the survival of hip prostheses in the Norwegian Arthroplasty Register

O Furnes¹, S A Lie², S E Vollset², L B Engesaeter¹, L I Havelin¹

¹Department of Orthopaedics, Haukeland University Hospital, Bergen, Norway, ²Division for Medical Statistics, Department of Public Health and Primary Health Care, University of Bergen, Norway.

It has been postulated that total hip replacements (THR) in patients with some hip diseases have a higher revision risk than others and that a special pattern of revision is seen.

Patients and methods: We studied the revision rates for THR (n=43306) in different hip disease groups reported to the Norwegian Arthroplasty Register during the years September 1987 – January 1997. Analyses were done by the Kaplan-Meier method and the Cox model. The risk of revision is given with reference to primary coxarthrosis.

Results: In an unadjusted analysis of the total material we found significant differences among the hip disease groups, but most of the differences disappeared when adjusting for the use of cemented/uncemented prostheses. In a subgroup of patients with Charnley prostheses with high viscosity cement (n= 17547), with all causes of revision as endpoint, the prostheses in sequela after hip fractures had 1.6 times higher risk of revision (p=0.000 1), prostheses in patients with dysplasia without dislocation had 0.57 times lower risk of revision (p=0.02), and in patients with dysplasia with dislocation 2.0 times higher risk of revision (p=0.04). With revision due to aseptic loosening of the cup as endpoint, the prostheses in the group with dysplasia with dislocation had a 5.1 times higher risk of revision (p=0.003). With revision due to aseptic loosening of the stem as endpoint, the prostheses in the dysplasia without dislocation group had 0.54 times lower risk of revision (p=0.04). With revision due to luxation as endpoint, the prostheses in sequela after hip fractures had 3.6 times higher risk of revision (p<0.0001), and the prostheses in the patients with dysplasia with dislocation had 5.8 times higher risk of revision (p=0.02).

Conclusion: Most of the differences in prosthesis survival between the groups of hip diseases could be explained by the increased use of poor performing uncemented prostheses in some disease groups. In patients with Charnley prostheses we found a higher risk of revision among patients with sequela after hip fracture and dysplasia with total dislocation, and lower risk in dysplasia without dislocation with all causes of revision as endpoint, however the differences were small. Some hip diseases show a characteristic pattern of revision.

11. Increased migration of the SHP prostheses

Bo Nivbrant, Johan Kärrholm

Dept of Orthopaedics, University of Umeå and Göteborg, Sweden

Considering the excellent results of cemented hip prostheses today, new implants should be very well tested before being put on the market. The SHP prostheses (Biomet) has gone through extensive pre clinical testing and the aim of this study was to measure the early migration in a small clinical series using radiostereometry (RSA).

Methods: 42 patients (median age: 67 yrs range 50- 80) with osteoarthritis of the hip and planned for a cemented THA were randomly allocated to either a SHP (Biomet) or a SP2 (Link) prostheses. Both stems were made of Co-Cr and matte. The SHP stem is thin, collarless, tapered, anteverted and uses spacers and a centraliser. The SP2 stems are anatomically shaped, collared, thick and are well documented in the Swedish National Registry.

All hips were operated with same technique by the same surgeon. Tantalum markers were inserted into the implants, cement and bone and RSA measurements done after one week, 6, 12 and 24 months.

Results: After 2 years (17+17 hips evaluated) the mean migration (SP2/ SHP) of the cups reached 0.19/ 0.26 mm medial-laterally, 0.21/ 0.34 mm proximal-distally and 0.19/ 0.16 mm anterior-posteriorly (n.s., Mann-Whitney's U-test). The mean rotations around the X, Y and Z axes were 0.38/ 0.40°, 0.44/ 0.36° and 0.44/ 0.73° (n.s.).

The stem subsidence reached mean values of 0.04/ 0.56 mm, SP2/SHP ($p < 0.0005$). Most of the SHP stem subsidence (0.49 mm) occurred inside the cement mantle. The corresponding rotations reached 0.53/ 2.33° in ante-retroversion ($p = 0.009$) and 0.13/ 0.42° in varus-valgus (n.s.). Migration of the SHP stem correlated positively to a wide femoral canal ($p = 0.02$ $R^2 = 0.6$ Stepwise linear regression).

Discussion: The SHP stem is a shape closed but uncollared design constructed for to minimise interface stress concentrations. Unexpectedly it displayed pronounced subsidence, which increased with the diameter of the femoral canal and the amount of bone cement. In previous RSA studies only the fully tapered and polished Exeter stem has displayed a subsidence of the same magnitude (1.0 mm at 12 months, unpublished obs), and no other has shown such a high retroversion as the SHP. This stem debonding might be due to a poor cementation of the SHP stems, but since the cement mantle itself was very well fixed to the bone it does not seem to be the likely explanation. However, the thicker cement mantle obtained with SHP stems might result in a more pronounced cement shrinkage and increased interface porosity, leading to a stem debonding and subsidence. If so, it might be favourable to use larger and pre heated stems at cementation for to reduce debonding and subsidence. Together with a polished rather than a matte surface this might reduce the risk for increased third body wear in the SHP stem design.

Until the clinical effects of the comparatively high migration values of the matte SHP stem has been completely eval-

uated, we think that the use of this design should be restricted to well control studies.

12. Excessive polyethylene wear with a metalbacked acetabular cup

Per B Thomsen

Holstebro Central Hospital, Denmark

Polyethylene wear has proved to be one of the most significant clinical problems jeopardizing the results after total hip arthroplasty. In a consecutive series of 382 uncemented hip arthroplasties with the porouscoated AML acetabular cup (325 primaries and 57 revisions) 42 hips (11%) were reoperated after 6 (2-9.5) years because of excessive polyethylene wear. Osteolysis was found around 29 cups and proximally around 24 stems and 4 stems were revised. In 26 hips the cup was revised and in 16 only the liner was exchanged, but all the heads were changed and downsized if possible. Factors with a significant negative bearing on the extent of wear were primary arthroplasty, a 32 mm's head and a pressfit stem. The patients were followed for nearly 8 (5-10) years and postoperative serial radiographs showed no progression of osteolysis up to 62 months and the Harris Hip Score averaged 96 points after 31 months. It is concluded that metalbacked acetabular cups with thin polyethylene liners and defective congruence between liner and shell show an unacceptable high frequency of excessive polyethylene wear necessitating reoperation.

13. Primary hip arthroplasty with the Exeter prosthesis and Boneloc cement

Per B Thomsen

Holstebro Central Hospital, Denmark

Fixation of hip prostheses with Boneloc cement has in some series resulted in catastrophic rates of aseptic loosening, but prosthetic design seems to have a great impact on the frequency of early revision. In a consecutive series of 429 Boneloc cemented primary Exeter hip arthroplasties the first 129 hips were clinically and radiographically examined after nearly 5 years. Patients own evaluation showed 89% good results and the Harris Hip Score averaged 87.6 points. Two stems and 2 cups had been revised because of aseptic loosening and radiographically another 3 stems and 2 cups were definitely loose. A questionnaire was answered by 94.5% of the remainder patients shortly after a very emotionally charged debate about Boneloc in the Danish media. Not surprisingly, patients own evaluation was significantly impaired compared to the clinical study, but a new follow-up examination of some of the most unsatisfied patients showed that most of their dissatisfaction was due to fear and uncertainty concerning their hip. Nearly 3-7 years after implantation only 5 Exeter stems (1.1%) and 9 cups (2.1%) have been

revised because of aseptic loosening and the cumulative survival of both components with revision for any reason as end point was 93% at 7 years. These results compare favourably with "the golden standard".

Session 3: Whiplash

14. A modified Swedish version of the Neck Disability Index

Birgitta Ackelman, Urban Lindgren.

Depts. of Physiotherapy and Orthopedics, Huddinge Hospital, Huddinge, Sweden

There is no validated Swedish instrument for evaluation of neck disorders. The Neck Disability Index (NDI) is a self administered instrument in English created in Canada. The NDI has a high test-retest reliability, good internal consistency and construct validity. Concurrent validity is good assessed by the correlation to a visual analogue scale rating improvement in activity.

In Sweden the Disability Rating Index (DRI) has been used for evaluating neck disorders, but there is a need for more specific instruments. This study was designed to test a previously used Swedish version of the NDI and our own modified translation.

Materials and methods: 20 patients (male/female, 7/13) with chronic neck disorders, 20 (10/10) with no neck but other musculoskeletal disorders and 19 (11/8) with acute neck disorders. Forms were given or sent to the patients on five separate occasions. The instruments were DRI, VAS pain, VAS overall activity and SF -36.

Results: Some items in the previously used Swedish version of the NDI were occasionally misunderstood, which decreased the specificity. The modified version appeared to be adequate for a Swedish-speaking group of patients.

Conclusion: The actual translation and modification of the NDI can be considered to be useful in a Swedish population for evaluation of neck disorders.

15. A prospective study on the Quebec classification as a predictor for the outcome after whiplash injury

Jouko Kivioja¹, Urban Lindgren¹ and Irene Jensen²

¹Department of Orthopedics, Huddinge hospital, Stockholm, Sweden and ²Section of Personal Injury Prevention, Karolinska Institute, Stockholm, Sweden

The Quebec group in 1995 suggested a new classification (whiplash association disorders, WAD) which is assumed to give information about the prognosis. There is however not yet data to support this assumption.

Material and methods: All cases of cervical sprain seen in any of the emergency hospitals in the southern region of Stockholm were studied (e.g. cervical range of motion, pain intensity, pain drawing, neck disability index (NDI), quality of life according to SF-36 and sick leave).

Results: 130 patients, 66 men and 64 women have now been followed for one year after the injury. The median age was 34 (18–58) years. The distribution according to the

WAD-classification was: Grade I 13%; Grade II 29%; Grade III 8%. The follow-up evaluation showed that the information gained by the WAD-classification is limited.

Discussion: This is a prospective study of consecutive cases. It demonstrates the difficulties inherent in the diffuse character of this disorder and the difficulties in predicting the outcome.

Conclusion: The usefulness of the WAD-classification for the prediction of the outcome after whiplash injuries is limited.

16. High-dose methyl-prednisolone prevents extensive sickleave after whiplash injury—a prospective randomised double-blind study

Göran Toolanen, Kurt Pettersson, Christer Hildingsson

Dept. of Orthopaedics, Umeå University Hospital, S-901 85 Umeå, Sweden.

Whiplash injury often results in chronic symptoms. The management of whiplash injuries is controversial and pharmacological therapy has been poorly evaluated. Recent reports indicate dysfunction of the central nervous system in a proportion of cases. Methyl-prednisolone given within 8 hours to patients with spinal cord injury improved outcome. This regime was also followed in our randomised trial on whiplash cases after car accident.

Methods: A prospective randomised double-blind study of high-dose methyl-prednisolone compared with placebo was conducted. Forty patients entered the study, 20 in each group, 22 men and 18 women with a mean age of 35 (19–65) years, treated at our department because of a whiplash injury after car accident. The patients were enrolled if the diagnosis was completed and the treatment begun within 8 hours after injury. Disabling symptoms, severe enough to make the patients unable to return to work, number of sick-days before and after injury and sick-leave profile after injury were used as parameters for evaluation of the effect of treatment. Baseline demographic data was controlled for when statistical analysis was performed.

Results: At 6 month follow-up there was a significant difference between the actively treated patients and the placebo group concerning disabling symptoms ($p=0.047$), number of sick-days ($p=0.01$) and sick-leave profile ($p=0.003$).

Conclusions: We conclude that acute treatment with high-dose methyl-prednisolone might be beneficial for prevention of disabling symptoms after whiplash. However, the number of patients included in this study is small, consequently further prospective controlled studies are needed.

17. Trigeminal sensory disturbances in whiplash patients

Christer Hildingsson, Ylva Fredin, Martin Knibestöl, Göran Toolanen

Depts of Orthopaedics, Rehabilitation Medicine and Clinical Neurophysiology, Umeå University Hospital, S-901 85 UMEÅ, Sweden.

The pathophysiology of chronic symptoms after whiplash injury is unknown. Clinical and animal studies have shown that trauma to the cervical spine might cause injuries to neural structures.

The aim of the present prospective investigation was to study the cutaneous sensibility for vibration and temperature in the trigeminal area and its relation to the symptoms and clinical outcome in whiplash patients.

Patients and methods: 43 patients with a whiplash injury due to car accidents entered the study. The first neurophysiological examination was performed with a mean of 6 weeks after injury. The patients were examined with a quantitative sensory test for vibration and temperature in the trigeminal skin area. 34 of the 43 patients returned for a follow-up and a second neurophysiological examination on average 60 (48–72) months after the accident. 9 patients did not attend the follow-up. 5 patients had been involved in new accidents and were excluded. 4 patients declined the follow-up examination. At follow-up symptoms were scored for each patient and the relationship between the neurophysiological data and the symptoms were analysed.

Results: At initial examination 30 patients had normal values of vibration and temperature and 13 had pathological test results. 11 of these were still pathological at follow-up. 1 was improved and 1 did not attend the follow-up examination. 5 patients had changed from normal to pathological test results. Thus 16 of the 34 follow-up patients had pathological test results.

The statistical analysis revealed a significant correlation between the severity of symptoms and the temperature and vibration sensory disturbances in the trigeminal area.

Conclusion: Cutaneous sensory disturbances in the trigeminal area diagnosed short time after accident in patients with whiplash injury persist over time. The symptom score was significantly higher in patients with cutaneous sensory impairment over the trigeminal area.

Session 4: Hip arthroplasty

18. Fixation and bone remodelling of a low modulus stem

Christian Anderberg, Johan Kärrholm, Henrik Malchau, Jonas Thanner, Peter Herberts

Dept. of Orthopedics, Sahlgrenska University Hospital/
Sahlgrenska Göteborg Sweden

This study aimed to measure fixation and bone remodelling of cemented and uncemented metallic or composite stems using radiostereometric analysis (RSA) and dual energy x-ray absorptiometry (DEXA).

Materials and methods: 56 patients (26 male, 30 female, median age 56, 38–70 yrs.) with non-inflammatory arthrosis of the hip were stratified in 2 groups based on femoral canal width ≤ 14 mm (Group 1 / 2). Further stratification in each group was based on gender, age and presence of primary or secondary arthrosis. Patients with a narrow canal received a cemented Option stem (O) or an uncemented Anatomic (A) stem (proximal porous surface with hydroxyapatite/tricalcium phosphate-HA/TCP coating and coating with pure HA distal to the pad leaving one third of the stem polished). Patients with a wider canal received either of these 2 designs or an uncemented EPOCH (E) stem. This design has a central core made of cobalt-chromium-molybdenum alloy, which is surrounded by 2 layers. One inner layer is made of polyaryletherketone. The outer layer consists of porous fibre metal made of commercially pure titanium (pore size: 300–500–600 microns). The proximal 2/3 of the stem was coated with HA/TCP (75% \pm 20% HA). The patients were examined with RSA postoperatively, after 3, 6 and 12 months. DEXA

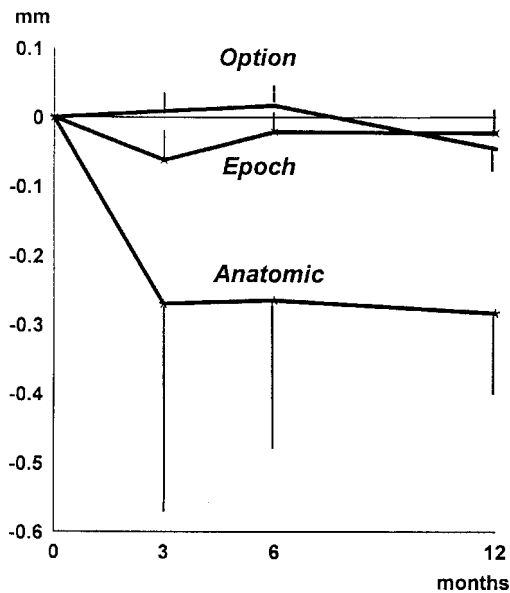


Figure 1. Proximal (+) - distal (-) migration of the 3 stem designs. All cases included. Mean S.E.

examinations were done postoperatively and after 1 year. Harris hip score were used at the clinical examination.

Results: Neither the subsidence nor the rotations of the stems differed at the one-year follow up (separate analysis of Group 1, 2 or Group 1+2, n.s.; Kruskal-Wallis test) (Fig.). In the group with a wide canal the cemented stems tended to lose more bone in Gruen region 6 compared to the 2 other cementless designs (O/A/E = -18/ -11/ -9 %; Group 2, $p < 0.05$, Kruskal-Wallis test). The Anatomic stems also tended to lose more bone in region 7 compared to the EPOCH design (E/A = -19/-38%; Group 2, $p < 0.05$). The clinical results did not differ when the 2 groups were analysed separately.

Conclusion: Contrary to previous designs of elastic stems the EPOCH design displayed minor micromotions during the postoperative year. Further on the elastic stem tended to lose less bone medially than the other 2 designs. This could be an effect of increased elasticity.

19. Arthrography for the diagnosis of abductor avulsion after the Hardinge approach in hip arthroplasty

Pekka Ylinen, Timo Paavilainen, Magnus Landtman and Kaj Tallroth

ORTON Orthopaedic Hospital, Invalid Foundation,
Helsinki, Finland

The direct lateral approach by Hardinge (1982) involves splitting and detachment of the gluteus medius muscle at the anterior aspect of the greater trochanter. Avulsion of the reattached gluteus medius results in abductor weakness, limp with positive Trendelenburg test and even pain. The aim of the present study was to examine the accuracy of arthrography in the diagnosis of abductor avulsion after total hip arthroplasty.

Patients and methods: In 48 consecutive patients a hip arthrography was performed because of suspected abductor avulsion. Arthrography was considered positive if there was a leakage of contrast medium from the joint to the trochanteric bursae. Surgery was indicated according to clinical and arthrographic findings in 27 women and 6 men.

Results: The arthrography was positive in 14 patients and negative in 19 patients. In all 14 patients with positive arthrography the operative finding was consistent with avulsion of anterior part of gluteus medius muscle. In 19 patients with negative arthrography the attachment of the gluteus medius was good in 10 patients. In 9 patients with negative arthrography the joint space was seen constricted by a cicatricial pseudocapsule which thus obstructed the pathway from the joint to the trochanteric bursae. The sensitivity of arthrography was thus 0.61 and the specificity 1.00.

Conclusion: A filling of the trochanteric bursae in arthrogram was diagnostic for an avulsion as there were no false positive findings. However, a negative finding is inconclusive and may be due to scarring or a pseudocapsule which hinder the leakage of contrast medium to the bursae.

20. Effectiveness of prescribed partial weight bearing—continuous registering of vertical loads using a new pressure sensitive insole

Magnus Tveit, Johan Kärholm

Dept. of Orthopedics, Sahlgrenska University Hospital, S-413 45 Göteborg, Sweden

Aim: To continually register vertical loads during walking with crutches on different surfaces to evaluate the effectiveness of prescribed pressure reduction.

Patients and methods: 6 men and 9 women aged 48-67 (median 58) operated with a total hip replacement were studied. An instrumental set-up including force-plate, measuring insole with two full bridge strain gauges, four amplifiers, one multi channel data logger, and personal computer was constructed. Each patient was first calibrated according to individual weight and foot anatomy on the force-plate with a proper insole. A physical therapist instructed the patient to use crutches corresponding to 30% of body weight. The patient walked a standardized distance (5 intervals: horizontal, up hill, down hill, up stairs and down stairs) with crutches. The vertical loads on the sensors were at all times logged at 250Hz. The procedure was repeated once.

Results: None of the patients managed to stay within the directives, even though 5 of them thought they had. Women had more steps with higher weight bearing than had men (all surface conditions: $p=0.02$, Mann-Whitney u-test, Fig. 1.) and tended to more often fail to keep the weight bearing within the directives ($p=0.05$). At the repeated examination the peak value (=10% interval of body weight where most of the observations occurred) remained the same in 22 of the 75

observed distances. In 37 of the distances this peak value had increased or decreased with 10% and in 16 the differences varied between 20 and 50% of body weight.

Discussion: Our findings indicate that the effectiveness of prescribing limited weight bearing is questionable, which has implications concerning the post surgery treatments after prosthetic and fracture surgery. Combined with other methods such as radiostereometry and measurements of bone mineral density new questions in the fields of joint replacement and fracture treatment can be addressed.

21. Correlation between the rotational position of the femoral stem in cemented total hip replacement and movement around its vertical axis at roengenstereophotogrammetry

K L Hermann¹, G Flivik³, N Egund^{1,2}, L Ryd³, K Jonsson⁴

Depts. of Radiology, University Hospitals of Copenhagen¹ and Aarhus², Denmark and Orthopedics³ and Radiology⁴, University Hospital of Lund, Sweden

Migration of prosthetic components has been shown to be a sensitive predictor of future loosening [1, 2] and in total hip replacement (THR) especially the rate of rotational migration may be decisive [3]. We present preliminary results on the relationship between such rotational migration and the postoperative femoral neck anteversion angle (FNA).

Material and methods: In a roentgen stereophotogrammetric (RSA) study of cemented THRs (n=54) postoperative 3-D CT-measurements [4] of FNA (n=49) were made. The 1-

Percentages of all steps

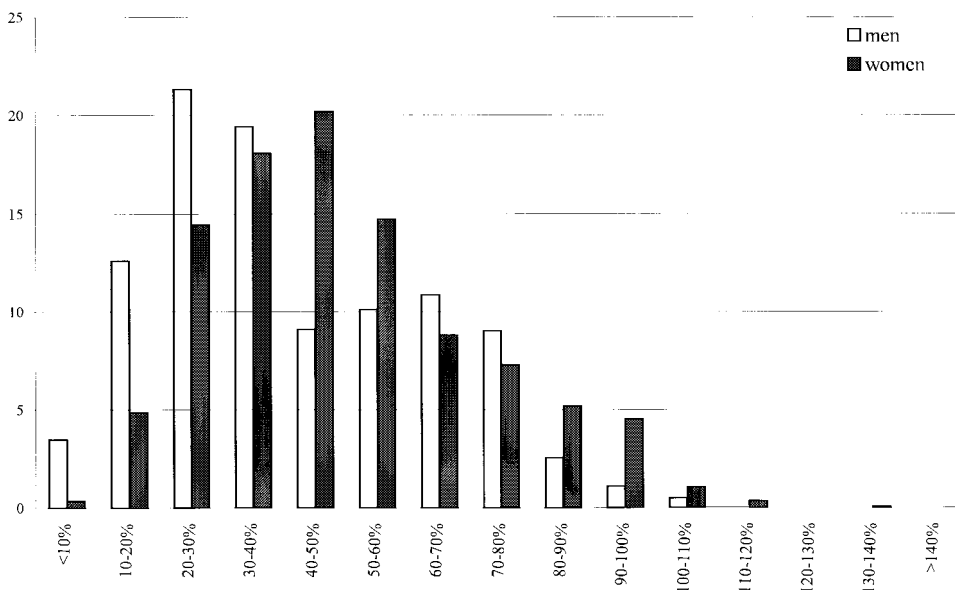


Figure 1. The distribution of all the steps in 10% intervals of body weight irrespectively of the surface conditions. Mean value of 2 observations for each patient.

year results of 17 femoral stems are presented.

Results: All except one of the femoral stems rotated towards retroversion with a mean of 1.5° (range: -0.9°–3.8°). The mean postoperative FNA was 17° (0°–42°). There was a significant inverted correlation between the magnitude of the rotation and the postoperative FNA, $r=-0.49$ ($p=0.047$). The difference between the means of those stems, which rotated less ($n=7$, mean FNA=27°) and those which rotated more ($n=10$, mean FNA=11°) than 1° was significant, $p=0.003$.

Conclusion: The results suggest that cemented femoral stems in THR positioned in little or no anteversion show large rotational movement towards retroversion. Further studies of these parameters with long-term clinical correlation regarding mechanical failure are indicated.

References: 1. Kärrholm J et al. J Bone Joint Surg 76B: 912-917, 1994.

2. Ryd L et al. J Bone Joint Surg 77B:377-383, 1995.

3. Nistor L et al. Clin Orthop 269:220-227, 1991.

4. Hermann KL and Egund N. Acta Radiol 38:527-532, 1997

22. The rotational position of different designs of femoral components in THR

KL Hermann¹, N Egund^{1,2}, JE Stürup³, P K Jensen³, JB Retpen³

Depts. of Radiology, University Hospitals of Copenhagen¹ and Aarhus² and Orthopaedics³, University Hospital of Copenhagen, Denmark

The rotational position of the femoral stem in primary total hip replacement (THR) resembles the preoperative femoral neck anteversion (FNA). We compare the rotational position of primary THRs with the rotational position of long curved femoral stems, which are most commonly used for revision THRs.

Materials and methods: Postoperative radiographic measurements of FNA in 202 hips with THR primarily using Bimetric[®] femoral components ($n=160$) (table).

Table. The type, number and mean FNA with range and SD of 160 THRs with a Bimetric[®] femoral component

Type of femoral component	n	FNA	Range	SD
Standard straight non-cemented	59	21°	2°–46°	10°
Standard straight cemented	66	17°	-12°–34°	9°
Long curved non-cemented	22	6°	-10°–27°	11°
Long curved cemented	13	13°	16°–36°	17°

Results: The mean FNAs appear in the table. The difference between the rotational position of non-cemented standard straight and long curved femoral components was significant, $P<0.0001$. There was no significant difference between cemented standard straight and long curved femoral components, and no significant difference between cemented and non-cemented femoral components.

Conclusion: The design without a build-in neck anteversion of the long curved femoral component facilitates this component to be positioned into slight or no anteversion in non-cemented THRs.

23. 10 years of Lubinus Interplanta total hip arthroplasties—survival-rate, patients' evaluation and reexamination

J Frederik Froen, Frithiof Lund-Larsen

Dept. of Surgery, County hospital of Laerdal, N-5890 Laerdal, Norway

This quality assurance study presents results of total hip arthroplasties at the County hospital of Laerdal. A small hospital that serves a population of only 25–30,000, and the only in Norway using Lubinus Interplanta.

Materials and methods: 332 Lubinus Interplanta implanted in the period 1987–1996 were included. Kaplan-Meier survival curves (1) based on reoperations reported to the Norwegian arthroplasty register (2) were completed with a slightly altered Dawson's questionnaire (3) to all patients retrospectively, and clinical and radiographic reexamination of the subjectively least successful fifth (18%) of arthroplasties.

Results: The estimated survival of Lubinus Interplanta versus aseptic loosening was 99.6% after five years, and 98.7% after ten years. The total revision-rate was 0.7% after five years, and 1.6% after ten years. With a responderate of 95%, patients reported a very substantial improvement of life quality and functional ability one to ten years postoperatively. Patients' perceptions demonstrated that indications for surgery, and results, were similar to results from other investigators. Symptoms increased for each year postoperatively. There was a strong correlation between the level of symptoms reported, and objective results at reexamination including loosening of prostheses. The survival-rate after reexamination showed no significant discrepancy compared to results based on figures from the Norwegian arthroplasty register.

References: 1. Kaplan EL, Meier P. Nonparametric estimation from incomplete observations. J Am Stat Assoc 1958; 53: 457-481.

2. Havelin L.I. Hip arthroplasty in Norway 1987-1994. The Norwegian arthroplasty register. Thesis, Department of surgery and Section for medical informatics and statistics. University of Bergen, Norway.

3. Dawson J, Fitzpatrick R, Carr A, Murray D. Questionnaire on the perceptions of patients about total hip replacement. J Bone Joint Surg (Br) 1996; 78-B: 185-190.

24. Progressive osteolysis after PCA cementless total hip arthroplasty—10-years follow-up of 32 cases

P Revald, P Kjaersgaard-Andersen, U Lucht

Section for Hip Surgery, Dept. of Orthopedics, Aarhus University Hospital, Aarhus, Denmark.

To evaluate the clinical and roentgenographical outcome 10 years after total hip arthroplasty with the cementless porous-coated anatomical (PCA) prosthesis.

Materials and methods: From August 1985 during April 1987, 32 consecutive "first generation" PCA total hip prostheses were implanted in 31 patients. The Harris Hip Score (HHS) was used to evaluate the patients preoperatively and at each follow-up examination. Roentgenograms were obtained the first day after surgery and at each follow-up. Clinical and roentgenographical data from each follow-up were compared to the one year data. Furthermore, the polyethylene wear were measured seven and 10 years after surgery. The Fisher's Exact Test was used to compare data. P-values < 0.05 were considered significant.

Results: Preoperatively, all patients had a poor HHS (median 37, range 9–66). Ten years after surgery, 86% had a good or excellent score (HHS > 79). Progressive roentgenographical changes were observed, in particular severe periprosthetic osteolysis and excessive wear of the polyethylene liner. Significant progressive osteolysis was observed between one year and 10 years after surgery ($p=0.00005$), with 86% having osteolysis after 10 years. Wear of the liner up to 0.4 mm/year was observed. Polyethylene wear correlated significantly to severe osteolysis ($p<0.003$). Revisions were planned in eight cases due to severe femoral osteolysis and acetabular cup loosening. The overall failure-rate 10 years after surgery was 27%.

Conclusion: Data from the seven and 10 years examinations have confirmed, that this prosthesis cannot be recommended for implantation due to massive polyethylene wear and periprosthetic osteolysis.

Session 5: Spine

25. Mechanical and histological analysis of bone-pedicle screw interfaces—titanium versus stainless steel

Finn Bjarke Christensen, Changtai Sun, Michel Dalstra, Flemming Sejling, Søren Overgaard, Cody Bünger

Orthopaedic Research Laboratory, University Hospital of Aarhus, Denmark

Almost all spinal implant systems are made of stainless steel (Ss), but titanium (Ti) devices are marketed with increasing frequency and costs. Until now, there are few studies analysing bone-pedicle screw interfaces in unloaded models.

The aim of this study was to compare histologically and mechanically the effect of pedicle screw fixation between Ti and Ss in a loaded mini-pig model.

Materials and methods: Eighteen adult mini-pigs underwent posterolateral fusion at L3/L4 and were randomized into two groups (CCD-Ss implants and CCD-Ti implants). The pigs were killed after 3 months. Histomorphometry was determined on 50 Fm thick sections of a blinded observer. Bone screw interface and bone purchase were examined. Mechanical testing was done by torsional test and pull-out test.

Results: Torsional tests showed significant higher stiffness in the Ti-group ($p<0.05$). The pull-out tests revealed no differences among the 2 groups. Bone direct contact with the screw was 29% (Ss) and 43% (Ti) ($p<0.002$). There were no differences of the bone purchase between groups.

Conclusion: Ti-pedicle screws had better interface bone binding than that of Ss. Pull-out tests seem not valuable when comparing screw purchase of different materials.

26. A long-term (4–12 years) follow-up study of surgical treatment of lumbar spinal stenosis

Michael Corneffjord, Gunnar Byröd, Helena Brisby, Kjell Olmarker and Björn Rydevik

Dept. of Orthopaedics, Sahlgrenska University Hospital, S-413 45 Goteborg, Sweden.

There are sparse data available regarding the long-term results of surgery for lumbar spinal stenosis. The aim of this study was to evaluate the long-term clinical outcome and possible complications of decompressive surgery of spinal stenosis, with special reference to possible differences between patients undergoing fusion, with or without instrumentation, or decompression alone.

Patients and methods: All 124 patients who underwent decompressive surgery for the first time for central and/or lateral spinal stenosis at our department between 1982 and 1991 were included in the study. At the time of follow-up, 6 patients were deceased and 22 lost to follow-up for other reasons. 96, i.e. 81% of the patients were reexamined by an independent investigator and assessed with a questionnaire.

The mean follow-up time was 7.1 (4.0–12.2) years and the mean age at follow-up 64.4 (29–87) years.

Results: 42% of all patients underwent decompression only and 58% decompression and fusion. 67% of the fusions were instrumented. Four patients had wound infections (2 instrumented fusions, 1 uninstrumented fusion and 1 without fusion). At follow-up, 65% of all patients were subjectively satisfied, 25% dissatisfied and 10% uncertain. Subjective low back pain and leg pain, evaluated with VAS 0–100, was 33.9 (SD 34.4) and 35.8 (SD 32.0) respectively. Preoperatively, 88% of the patients had constant or daily leg pain preoperatively compared to 43% at follow-up. Constant or daily low back pain was reported by 83% of the patients preoperatively compared to 45% at follow-up. At follow-up, 44% of the patients had a walking capacity of more than 5 km, compared to 4% preoperatively. 18% reported a walking capacity of less than 200 m at follow-up, compared to 67% preoperatively.

Discussion: The percentage of patients with satisfactory results in the present study are in accordance with the results of the few earlier long-term follow-up studies of surgery for lumbar spinal stenosis, incl. one meta-analysis of the literature. Considerable improvement of walking distance at follow-up was found in most patients. There were no obvious differences in the clinical outcome between patients who were fused and those who were not. Neither were any significant differences between instrumented fusions compared to uninstrumented fusions found.

27. Effects of non-steroid anti-inflammatory drugs in experimental spinal nerve root injury

Michael Corneffjord¹, Koji Otani^{1,2}, Kjell Ollmarker¹ and Björn Rydevik¹

Depts. of Orthopaedics, ¹Sahlgrenska University Hospital, Gothenburg, Sweden and ²Fukushima Medical College, Fukushima, Japan

Spinal nerve root injury can be induced by chronic compression and/or nucleus pulposus (NP). It has been demonstrated experimentally that autologous NP can induce significant changes in nerve root morphology and function. High-dose administration of methylprednisolone, a potent anti-inflammatory drug, has been shown to reduce NP-induced nerve root injury dramatically. Secondary inflammatory changes, induced by microvascular permeability changes and leakage of inflammatory mediators into the endoneural tissue, have been proposed to be of importance in the pathophysiologic mechanisms induced by chronic compression of spinal nerve roots. The aim of the present study was to assess the effects of two potent non-steroid anti-inflammatory drugs, diclofenac and ketoprofen, in experimental nerve root injury induced by chronic compression or NP in a pig model.

Material and methods: NP was harvested from a lumbar disc in 18 pigs (bw 25–35 kg). The 1st sacral nerve roots (S1) were then bilaterally exposed and NP was applied locally. In another 12 pigs, an ameroid constrictor was gently slid

onto the S1-nerve root. Fourteen of the pigs, 7 with a constrictor and 7 exposed to NP, were treated with daily intramuscular injections of ketoprofen for 7 days. 5 pigs exposed to NP were treated with daily intramuscular injections of diclofenac. As controls, 5 pigs with a constrictor and 6 NP exposed pigs did not receive any drug treatment. After 7 days, muscle action potentials were recorded and the nerve conduction velocity (NCV) over the exposed nerve root area was determined.

Results: In the constrictor series, NCV was significantly higher ($p < 0.05$, Student's t-test) in pigs treated with ketoprofen compared to untreated, 57 ± 16 m/s vs. 35 ± 15 m/s. In the nucleus pulposus application series, NCV was significantly higher ($p < 0.05$) in pigs treated with diclofenac compared to untreated, 57 ± 7 m/s vs. 38 ± 18 m/s.

Discussion: The results of the study indicate that non-steroid inflammatory drugs have effects on the pathophysiologic mechanisms involved in spinal nerve root injury induced by chronic compression or nucleus pulposus. However, the pharmacological and pathophysiological mechanisms involved in these treatment effects are incompletely known and need to be further investigated.

28. Mobility provocation of the lumbar spine evaluated by RSA

Ragnar Johnsson, Paul Axelsson, Björn Strömqvist

Dept. of Orthopedics, Lund University Hospital, S-221 85 Lund, Sweden.

To evaluate by radiostereogrammetric analysis (RSA) the effect of spinal loading on lumbar segmental motion.

Patients: 10 patients with no prior spinal surgery and with possible lumbar segmental pain on degenerative basis had an external fixation test using the Magerl frame including percutaneous application of metallic markers in L3, L4, L5 and S1 for RSA as a prognostic measure for fusion. One month after the fixation test RSA was performed.

Method: The marked vertebrae were examined by RSA in the positions: 1/ supine, 2/ normal standing, 3/ standing with 20kg sandbags on the shoulders and 4/ sitting. The intervertebral movements in each lumbar segment induced by change from supine to the other three positions were calculated.

Results: Sitting induced more pronounced intervertebral movements than normal standing or standing with sandbags. Sitting could induce intervertebral translations up to 6 mm along the vertical and/or sagittal lumbar axes as well as rotations up to 12° around the transverse axis in all three segments. In general, the amount of vertical translation was similar in the three segments and the amount of anteriorly directed sagittal translation as well as transverse rotation increased in distal direction.

Conclusion: RSA evaluation of intervertebral movements induced by positional change from supine to normal standing and to sitting should be a powerful tool in providing differentiated information on lumbar segmental motion.

29. Surgery vs. conservative treatment in adult spondylolisthesis—a prospective randomized study

Hans Möller, Rune Hedlund

Dept. of Orthopaedic Surgery, Karolinska Institute, Huddinge University Hospital, 141 86 Huddinge, Sweden

Satisfactory results of spinal fusion in spondylolisthesis have been reported in many studies. However, there are no controlled studies published. Furthermore, it is controversial whether instrumentation of lumbar fusion improves outcome. The present study was designed to determine whether surgical treatment is better than physiotherapy, and whether instrumentation improves the outcome of posterolateral fusion.

Patients and methods: 111 patients, 54 women and 57 men, aged 18-55 years, with adult isthmic spondylolisthesis with at least one year of low back pain, with or without sciatica were randomized to (1) physiotherapy, (2) posterolateral fusion, and (3) posterolateral fusion with transpedicular instrumentation (CD). The patients were followed at least 2 years. The mean age was 39 (18-55) years. Functional disability and pain were quantified by 12 and 2 VAS, respectively.

Results: At 2 years follow up the surgical group (2+3) reported lower disability ($p < 0.01$) and less pain ($p < 0.01$) than the conservative group (1). The functional disability improved in the surgical group ($p < 0.001$) but not in the conservative group. There were no statistically significant difference between instrumented and non instrumented group.

Conclusion: The present randomised controlled study of adult spondylolisthesis shows that fusion results in a superior functional outcome and less pain compared to conservative treatment. The results also show that instrumentation does not add to the clinical outcome.

Varia

30. Effects of arm suspension in simulated assembly line work

Per Wretenberg¹, Yi Feng², Wim Grooten²
and Ulf P Arborelius²

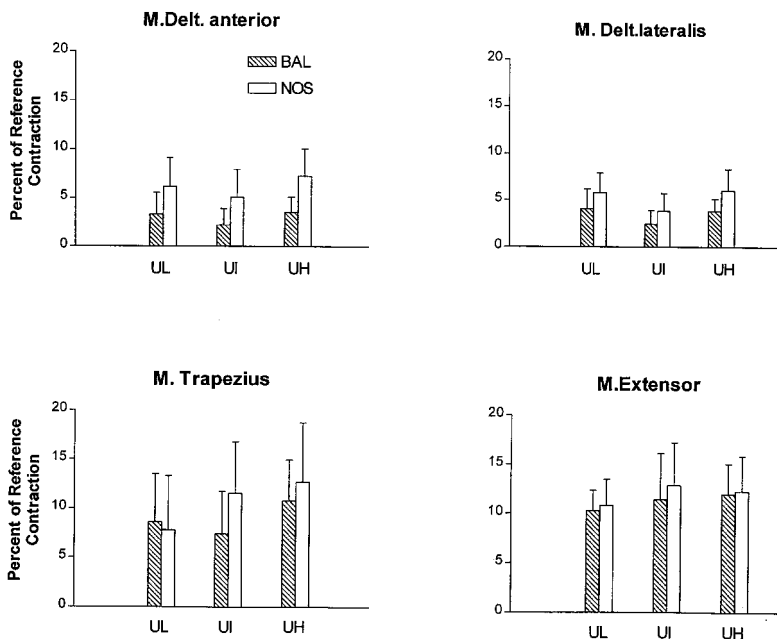
¹Dept. of Orthopaedic Surgery, Karolinska Hospital.

²Kinesiology Group, Dept. of Neuroscience, Karolinska Institute, Stockholm Sweden.

Arm suspension has been recommended for assembly line workers who have elevated unsupported arm positions, to prevent shoulder and neck problems. This study evaluates the biomechanical effects.

Material and methods: 12 healthy female subjects performed simulated assembly line work in three positions with and without forearm support of a balancer, a so called "K-block", that hung from a fixed horizontal bar. For motion registration a 3-D recording system (Selspot) was used and EMG of the deltoideus pars ant., deltoideus pars lat., trapezius pars descendens and extensor carpi radialis longus was recorded. The loading moment of force on the bilateral

Balancer vs No Support (EMG)



movement axes for the shoulder and elbow was calculated using fully dynamic calculation.

Results: The balancer gave a significant reduction ($p < 0.05$) of the muscular activity in the m. deltoideus ant. for all tasks. There was also a tendency to reduction of the muscular activity in the deltoideus lat. and trapezius muscles, Figure 1. Use of the balancer significantly decreased the trunk inclination and increased shoulder flexion. The loading moment of force was significantly decreased for all working situation when the balancer was used ($p < 0.001$).

Conclusion: The results show that the use a balancer greatly reduce the mechanical load on the shoulder and elbow joints. It also has the ability to reduce muscular activity. A balancer also creates changes in the working position and allows a more upright trunk posture because the arm can be held more stretched at a lower biomechanical cost than without support.

31. The Differentiation of osteofibrous dysplasia from adamantinoma of the tibia

B Kulinsky, K L Dirksen, A G Jurik, S Daugaard, O Myhre Jensen, J Keller, B Lund

Orthopedic Oncology Units, Rigshospitalet Copenhagen and University Hospital Århus, Denmark

The differentiation between osteofibrous dysplasia from adamantinoma is important for the choice of treatment and outcome. Osteofibrous dysplasia as a congenital anomaly may produce a bowing deformity and treatment depends only on the extent of deformity. Adamantinoma is a malignant tumor and has to be treated by wide excision. The radiological appearance of both lesions may be identical. Distinction can be made histologically, but may require immunohistochemical staining with cytokeratin.

Material and methods: We retrospectively reviewed 18 patients classified as monostotic fibrous dysplasia (14), intracortical haemanoma (2) and adamantinoma (2) from a 27 year period (1970–1997). All lesions were located in the tibia and/or fibula. The diagnoses were made by consensus by two orthopedic surgeons, two radiologists and two pathologists. We reexamined 6 patients by radiography and MR-scan of the tibia and fibula, CT-scan of the chest and open biopsy from the persistent intracortical lesions.

Results: After review the diagnoses were: monostotic fibrous dysplasia (4), osteofibrous dysplasia (6) and adamantinoma (8). The reexamined patients with an adamantinoma (5) showed no severe progression neither radiologically nor histologically and no dissemination. The mean follow up time for the adamantinoma was 11 (3–18) years. We performed one thoracotomy on a young female: the adamantinoma of her tibia had regressed during pregnancy, while the Ct-scan of her chest showed two intrapulmonary nodules. They were excised but found to be benign. The mean age of patients with fibrous dysplasia was 30 years (18–50), with osteofibrous dysplasia 14 (2–50) years and with adamantinoma 10 (5–18) years

Conclusion: The radiological soap-bubble in the anterior cortex of the tibia appears to be pathognomonic for the adamantinoma. It is important to distinguish the benign lesion from the malignant one at an early stage, because of the different treatment. MR-scan can show whether or not the tumor has penetrated the medullary canal. Wide surgical margin is essential to avoid local or distant recurrence.

32. Ilizarov method of bone transport in the treatment of tibial bone defects

Goran Turkovic, Milimir Kosutic, Srdjan Cvetanovic

Clinic of Orthopaedics, Clinic of Plastic Surgery and Burns, Military Medical Academy, Belgrade, Yugoslavia

High energy open fractures of the leg (war; traffic; industry) have significant soft tissue and bone damage with bacterial contamination. After primary surgical excision usually large defect of soft tissue and bone remains, making the treatment difficult with uncertain result. Ilizarov method of bone transport helps in limb salvage and regains the function of the leg as much as possible.

Materials and methods: 81 patients were treated with this method in the period from 1991. till 1997. 78 were men and 3 women, mean age 32 years (18 to 58). Soft tissue injuries were classified as Gustilo III B in 73 (90.1%) and Gustilo III C in 8 (9.9%) patients. Tibial bone defects ranged 4 to 21, average 9,2 cm. Fractures were primary elaborated and stabilized with unilateral external fixator. Soft tissue reconstruction was done afterwards: 38 (46.9%) local flaps; 27 (33.3%) free flaps; 3 (3.7%) cross-leg flaps and additional split thickness skin grafts. After soft tissue healing, unilateral fixator was removed and Ilizarov circular frame fixator was placed with construction for consecutive bilateral distraction-compression osteosynthesis. Tibial corticotomy was made through the longer fragment proximally 48 (59.3%); distally 30 (37%) or both 3 (3.7%). Distraction started on 7th. post-operative day at 1mm rate for 24 hrs.

Results: All bone regenerates healed well. In 61 patients complete union was obtained with average healing index of 42 days for 1 cm of bone defect. There were 20 (24,7%) non-unions in docking-site. In 13 patients we reoperated with new construction of Ilizarov apparatus (monofocal-compression) and with additional corticospongious bone grafting from iliac crest in 8 cases. Seven of these 13 healed and rest of them are still treated. One patient is walking with orthosis, one insisted on apparatus removal, one left to another institution and 4 patients are waiting for further treatment. We made one below knee amputation in the patient with 3 refractures and osteomyelitis. As a late complication 5 refractures occurred and all healed in PTB plaster.

We consider that bone transport due to Ilizarov method can provide excellent substitution of large bone defects. We must also emphasize that surgeon's familiarity with Ilizarov technique is mandatory, as well as the choice of patients, who are expected to cooperate throughout the long treatment.

Session 7: Fractures and traumatology

33. Influence of straight Dinamic nail on femoral 3-D curvature shape

R Komadina¹, M Vlaovic¹, M Galeazzi², A Perissinotto³

¹General&Teaching Hospital Celje, Slovenia; ²Citiefte, Bologna, Italy; ³Biomedical School, University of Padua, Italy

Intramedullary nail achieves 3-D deformation to adapt itself to anatomical procurvatum of femur. If plastic deformation occurred no static reaction force is produced, if elastic deformation occurred reaction force is produced with force F and moment M, inducing a straightening of anatomical procurvatum of femur. The nail does not induce any deformation without being deformed. Adaptation is possible but not probable if small diameter nail has been used.

Material and methods: 46 patients treated with Dinamic femoral intramedullary nail have been evaluated and tested postoperatively to investigate deformation of femur in sagittal plane. Theoretical simulation and clinical evaluation has been done by radiographs and computer programs. DEXA controls of particular cases have been performed.

Results: Variation of femoral curvature in sagittal plane after nail removal suggests that the elastic force due to the implantation of straight nail has trespassed bone resistance, achieving permanent deformation until nail removal. After nail removal this particular force does not exist anymore and bone remodeling due to Wolf's law occurs.

Conclusion: Correct preoperative evaluation of nail diameter and the correct amount of reaming reduces induced residual deformation of the procurvatum. Two different residual deformations can be observed and calculated by the measurement with radiographs: after intramedullary nailing and after nail removal.

34. Unreamed interlocking nailing in tibia fractures

Sacit TURANLI, Tuna ÖZYÜREKOGLU, Hamza ÖZER

Emergency Care and Traumatology Hospital, Ankara, Turkey

Better anatomic reduction, earlier mobilisation and consolidation, low rates of infection and malunion make intramedullary nailing first choice in most of the tibia diaphyseal fractures.

Materials and methods: 42 unstable tibia diaphyseal fractures, 24 closed and 18 open (8 Grade I, 9 Grade II, 1 Grade IIIA) were treated with unreamed interlocking nails between June 1995 and August 1997. The average age of the 38 patients (31 male, 7 female) were 40.3 (16–86). Patients with open fractures were managed with copious irrigation, adequate debridement and appropriate antibiotics were operated within 12 hours, whereas the closed fractures were op-

erated in 3.7 (1–9) days. Orthofix (39 fractures) or Broker® (3 fractures) unreamed tibial nail were used. 7 patients had head trauma, 15 patients had another injury. Minimally open reductions were done for 8 fractures. 9 fractures (21.5%) were locked proximally, 8 (19%) were locked distally and 25 (59.5%) were locked statically. The average follow-up time was 15.5 (5–30) months. The evaluation of the final results were made with Johner and Wruh's criteria.

Results: Healing (radiographical osseous union with painless weightbearing) was achieved in all but one (2.4%) patient within an average of 16.1 (10–34) weeks, - closed fractures: 15.0 (10–21) weeks; open fractures: 17.6 (10–34) weeks. The average union time was 13.6 (10–20) weeks in dynamically locked fractures, 17.2 (12–34) weeks in statically locked fractures and the difference was significant ($p < 0.05$). There were only 1 deep infection, 3 malunion. We have found 26 (61.9%) excellent, 13 (30.9%) good, 2 (4.8%) fair, 1 (2.4%) poor results according to the Johner and Wruh's criteria.

Conclusion: The results of unreamed interlocking nailing in unstable tibia fractures in our series is excellent or good in 92.8 % of patients. The advantages of the procedure are the stability of fixation, early mobilization with partial weight-bearing, minimal soft-tissue stripping and interlocking without the use of fluoroscopy. The importance of copious irrigation, debridement and antibiotic administration in initial care of open fractures for immediate ORIF must be impressed. The fractures should not be interlocked statically if it is not required.

35. The epidemiology of Achilles tendon rupture in a Danish county

Shirzad Houshian, Thomas Tscherning, Per Riegels-Nielsen

Department of Orthopedic Surgery, Esbjerg County Hospital, Esbjerg, Denmark.

The purpose of this study was to determine the epidemiology of Achilles tendon ruptures (ATR) with particular emphasis on describing age and sex distributions and its relation to sport activities in a Danish County.

Patients and methods: During the years 1984–1996, 718 patients with an acute ATR were registered in one of the Orthopedic Department in Ribe County in Denmark for primary treatment. The data collection was made in a retrospective fashion at five hospital, serving a population of 220.000 operated. The Hospital Discharge Registers and EHLASS were used to find all ATR. Student's t-test was used to test whether this correlation coefficient was significantly different from zero.

Results: There were 544 men (75.8 %) and 174 women (24.2 %). The average age was 42.1 (3–82) years. 643 ruptures (89.6%) were treated surgically, and 75 ruptures (10.4%) treated conservatively. 73% of the ruptures were related to sports, mostly badminton. The annual incidence of ATR increased from 18.2/10⁵ inhabitants in 1984 to 37.3/10⁵ in 1996, and this rise was related to sport. The peak inci-

dence in the sport-related cases occurred primarily in the age group 30–49 years and in nonsport-related occurred in the age group 50–59 years.

Discussion: The incidence of ATR is increasing, probably on account of increased interest for recreational sports. The sex ratio in our study disclosed higher proportion of females than reported in previous investigations. This phenomenon could be explained by increased activity among females.

36. Fasciocutaneous flaps in the treatment of soft tissue defects of the leg

Srdjan Cvetanovic, Goran Turkovic

Clinic of Plastic and Reconstructive Surgery, Clinic of Orthopaedics, Military Medical Academy, Belgrade, Yugoslavia

Among contemporary reconstructive procedures in treating soft tissue defects of the leg, fasciocutaneous flaps have the important place. In the period from 1991–1996 we treated 568 patients with soft tissue defects of the leg. In 172 patients (30.3%) we used fasciocutaneous flaps to cover the wound and deep structures of the leg and to enable future osteoplastic procedures where necessary. Proximally based flaps were used in 136 (79.1%) for covering soft tissue defects in the proximal or the middle third of the leg. Defects localized in the distal third were treated with 36 (20.9%) reversible fasciocutaneous flaps. Complications: 12 (7.0%) patients had marginal flap necrosis; 2 (1.2%) had partial necrosis and 3 (1.7%) reversible flaps necrotised. These complications were solved with additional surgery. In cases of marginal and partial flap necrosis, split thickness skin grafts were used. On the other hand, in 2 patients with total necrosis we performed cross-leg flaps and 1 had free (scapular) flap done. We found that local fasciocutaneous flap is relatively easy to perform and has small percentage of complications which can be solved with other available methods. Considering this, it is very reliable and maybe the best choice for reconstruction of soft tissue leg defects.

37. Intramedullary nailing in humeral shaft fractures—mechanical behavior after nailing with three different nails

Anders Mølster, Nils R. Gjerdet, Randi M Hole, Rolf M Strand and Leiv M Hove

University of Bergen, Surgical Institute and Section for Dental Biomaterials.

Intramedullary nailing of the humerus in case of shaft fractures has given less than satisfactory results, partly because of instability problems. Therefore we wanted to compare a new commercially available nail, Polarus (P), with our presently used Russell Taylor (RT) nails. The humerus is a non-weight bearing tubular bone which may be suitable for elas-

tic osteosynthesis. Therefore, solid polyacetal polymer (AC) nails with a greater flexibility than metal nails were included in the study.

Material and methods: Standardized midshaft fractures, with slightly oblique fracture lines were produced in 15 pairs of human humeri. Intramedullary nailing was performed with either 8 mm RT nails, P nails, or 10 mm polyacetal nails. The RT and P nails were locked according to the manufacturers' instructions; the AC nail with two standard 3.5 mm cortical screws after 2.5 mm pre-drilling through the cortical bone and the nail 4.5 and 5.5 cm from the fracture at either side.

Mechanical testing was performed as a non-destructive bending test (3 mm deflection), followed by torsional testing to failure (5°/s).

Results: The RT-nailed preparations exhibited a large initial instability (uncontrolled rotation, "play") in torsion. The median bending stiffness of the RT nail was 103 N/mm, 118 N/mm for the P nail, and 47 N/mm for the AC nail. In torsion, humeri nailed with RT nails had a median torsional stiffness of 0.36 Nm/degree, the corresponding value with the P nails was 0.97 Nm/degree, while the AC nail exhibited 0.22 Nm/degree. The stiffness of the bones nailed with P nails was statistically higher than that of the two other nails.

The median torsional moment at the point of failure was not significantly different between the three groups (RT: 11.2; P: 11.3; AC: 9.3 Nm). The corresponding angular displacement was significantly lower for the P nails (14.8 degrees) than for the other two groups (RT: 56.9; AC: 41.2 degrees). The initial portion of the moment/angle curve revealed a median "play" of 25 degrees in the RT-nailed preparations, compared with 2 degrees in those with P nails and 9 degrees with AC nails.

Discussion: The high stiffness and the resulting low angular displacement with P nails resulted in a stable and rigid complex, which may be considered advantageous. The uncontrolled rotation ("play") with RT nails, due to fact that the diameter of the distal locking holes in the nail were greater than that of the screw, may be considered a disadvantage. The influence of soft tissues may, however, change the effect in the clinical situation.

The AC-nailing was less stiff, but could take high angular displacements before failure. The amount of "play" was also insignificant, resulting in an elastic fixation. The clinical effect of this mechanical situation in the humerus is not known.

Conclusion: The Polarus nailing gave higher rigidity of the bone/nail construct than the Russell Taylor and polyacetal nails. The Russell Taylor nail exhibited a high amount of uncontrolled rotation ("play"). The polyacetal nails allowed a great elastic deformation before failure.

38. Fixation of unstable posterior pelvic ring fractures—a comparative study

Robert Gvozdenovic, Benny Dahl, Martin Gehrchen, Peter Blyme, Thomas Kivær and Erik Tøndevold

Spine-Trauma unit, Department of Orthopaedic, Rigshospitalet, Denmark

A number of techniques have been introduced to obtain reduction and fixation of posterior unstable pelvic ring fractures. Three surgical approaches have been described: open posterior, open anterior and closed percutaneous. The purpose of the present study was to compare the short term outcome using 3 different techniques.

Material and methods: 96 patients were operated on from January 1990 to December 1996. 38 patients were treated by open posterior technique using double COBRA plate (Group 1). 30 patients were treated by open anterior technique using an Olerud plate for anterior fixation of the SI-joint (Group 2). 28 patients were operated on posteriorly with percutaneous insertion of cannulated screws (Group 3). Outcome parameters were healing, infection, material failure, implant removal, neurological status, and iatrogenic neurological injury.

Results: Complete data existed on 73 patients. Median follow-up was 14 (3–52) months. In Group 1 11 patients had skin healing problems. In 7 of these patients revision of the wound was performed. 11 patients in Group 1 had the implant removed, primarily due to local problems. In Group 2, 1 patient had superficial wound infection and 1 patient had the implant removed. The corresponding figures in Group 3 were 0 and 4. There were no difference in fracture healing, deep infection, neurological outcome and operative risk of neurological injury.

Conclusion: These results show that the 3 techniques provide adequate fixation of unstable posterior pelvic ring fractures. Open posterior fixation with a double COBRA plate gives higher rates of superficial infection compared to closed percutaneous technique. Open anterior and closed percutaneous techniques have an acceptable number of complications. The percutaneous technique has the lowest rate of complication with satisfying results and should be preferred. Open posterior technique has an unacceptable high complication rate, and should be reserved for salvation of very difficult fracture patterns.

Session 8: Cervical spine

39. Distractive flexion injuries of the cervical spine treated via an anterior approach

Thomas Henriques, Claes Olerud, and Halldór Jónsson Jr¹

Departments of Orthopedics, Uppsala University Hospital, Uppsala, Sweden, and ¹Reykjavik University Hospital, Reykjavik, Iceland

Distractive flexion injuries of the cervical spine (DF; Allen and Ferguson 1982) have traditionally been operated via a posterior approach. However, disk material may be displaced into the spinal canal at the reduction maneuver compressing the cord, and a previous study have indicated more neck stiffness and pain after the posterior approach, why an anterior procedure may be desired. We have operated a series of DF injuries via an anterior approach including: disk excision, reduction, and fixation with the AO/ASIF Cervical Spine Locking Plate (CSLP) device, followed by a stiff collar for 6 weeks. The aim of the present study was to report the healing and complication rate in the series.

Patients and methods: The series consisted of 27 consecutive patients (5 women), 17–88 years of age. There were 6 stage 1 (DFS-1: increased distance between the spinous processes), 16 stage 2 (DFS-2: unilateral facet dislocation), and 5 stage 3 injuries (DFS-3: bilateral facet dislocation). There were 9 patients with tetraparesis (Frankel A-C); 1 in DFS-1, 4 in DSF-2, and 4 in DSF-3. The records were reviewed for complications. The patients were followed with plain x-ray at 3, 6, and 12 months after the injury.

Results: In DSF-1 all 6 patients were healed at 12 months. In DFS-2, 12 patients were operated on at 1 level; all were healed at 12 months. Four were operated at 2 levels; 2 developed a non-union at one level, resulting in one reoperation. In DFS-3, 1 patient died at 3 months; no healing data was recorded. Two of the 5 patients were healed at 12 months, whereas 2 had redislocated short after surgery (1–2 months) leading to reoperations with an additional posterior fixation.

Conclusion: The results of the present study indicates that a sole anterior decompression and fixation after reduction is sufficient for DFS-1 and one level DFS-2 injuries. In two levels DFS-2 and in DFS-3 injuries, however, anterior fixation does not seem to give enough stability.

40. The Olerud Cervical Fixation System—a study of safety and efficacy

Claes Olerud¹, Bengt Lind², and Bo Sahlstedt³.

Depts. of Orthopaedics ¹Uppsala University Hospital, Uppsala, and ²Gothenburg University Hospital, Gothenburg, and ³Department of Diagnostic Radiology, Uppsala University Hospital, Uppsala, Sweden.

To evaluate safety and efficacy of the Olerud Cervical Fixation System a one year follow up study of the first patients

treated with the system was done by an unbiased observer.

Patients and methods: There were 30 patients (14 women) with a mean age of 68 (37–85) years. Indications were rheumatoid arthritis in 10, spinal stenosis in 6, trauma in 6, metastases in 4, revisions in 3, and painful spondylosis in one patient. Short fusions were performed in 8 patients and long fusions in 22. Four patients were fused to occiput. C1-C2 fusion were performed in 3 patients. 19 of the 20 still alive were evaluated at follow up. One patient was deliberately fused in hyperlordosis, in the rest the alignment was acceptable.

Results: Primary stabilisation was achieved in all patients. 130 pedicle screws were used; one screw in Th2 was lateral to the pedicle, the rest was in correct position. 42 subaxial transarticular screws were used; there were no complications related to these. Two infections healed on conservative treatment. Loss of fixation and non-union developed in 2 patients. Malignant patients, and patients with myelopathy due to rheumatoid arthritis carried a high mortality risk.

Conclusion: The Olerud Cervical Spine Fixation System is versatile in posterior fixation of the cervical spine and has proven to be both safe and efficient.

41. Odontoid fractures in the elderly—high failure rate with anterior screw fixation

Susanna Andersson¹, Miriam Rodrigues²
and Claes Olerud¹

Depts. of ¹Orthopedics and ²Diagnostic Radiology,
Uppsala University Hospital, S-751 85 Uppsala, Sweden.

This study is a retrospective analysis of patients older than 65 years with odontoid fractures.

Patients and methods: The series consisted of 29 consecutive patients (18 women) with odontoid fractures with a mean age of 78 (66–99) years. 25 of the fractures were type II and 4 type III (Anderson and d'Alonzo 1974). Three patients also had ring fractures of C1. Twenty-six patients were neurologically intact, Frankel E, whereas 3 had neurological symptoms; 2 Frankel D and 1 Frankel C. Eleven patients were treated with anterior screw fixation according to Böhler, 7 with a posterior C1-C2 fusion. Ten patients with either minimally displaced fractures or with complicating medical conditions were treated conservatively.

Results: At follow up all 7/7 patients with posterior fusion had healed without any problems, whereas 8/11 of the patients treated with anterior screw fixation, and 7/10 conservatively treated patients were failures.

Conclusion: We conclude that anterior screw fixation according to Böhler is associated with an unacceptably high failure rate in the elderly population. Probable causes for failures may be osteoporosis with comminution at the fracture site, or stiffness of the cervical spine not allowing an ideal positioning of the screws. Also conservative treatment fails often. The method of choice seems to be posterior C1-C2 fusion.

42. Cotrel Dubousset Instrumentation in the cervical spine—an experimental study on the relation of hooks to the spinal cord

Teddy Fagerström¹, Rune Hedlund², Philippe Bancel³,
Roger Robert⁴, B Dupas⁵

¹Dept. of Orthopedic Surgery, University Hospital, Linköping Sweden. ²Dept. of Orthopedic surgery, Huddinge Hospital Stockholm Sweden. ³Dept. of Orthopedic Surgery, Clinique Labrouste, Paris France. ⁴Dept. of Neurotraumatology, ⁵Dept. of Radiology, Hôtel Dieu, Nantes, France.

Instability of the cervical spine, whether traumatic, degenerative, rheumatoid or neoplastic, may necessitate internal fixation. Several anterior and posterior methods are available today. Despite the common use of hooks in the lumbar and thoracic spine, its use in the cervical spine has been restricted, primarily because of fear of cord compression due to intrusion of hooks in the spinal canal. The purpose of the study was to assess the safety of using hooks for fixation of the cervical spine, by determination of the anatomical relation between inserted hooks and the spinal cord.

Methods: 13 cadavers from seven women and six men with no evidence of cervical spine disorder were included. The cervical spine was instrumented with Cervical Compact Cotrel Dubousset hooks and rods. The effect of the hook on the dura was studied by myelography of the intact spine with hooks inserted. A hemilaminectomy was performed at all levels in three cadavers with direct visual inspection and photography of the hook sites before and after excision of the dura. A CT scan was obtained in three cadavers. The ratio between the distance of maximal hook intrusion into the spinal canal and its diameter in the direction of the hook was calculated.

Results: Dural deformation was observed at four out of 80 hook sites. On visual inspection 14 out of 18 hooks were in contact with the dural sack. After removal of the dura, two hooks in one cadaver were in contact with the spinal cord. However, no deformation of the cord was observed. The mean hook intrusion in the spinal canal was 27% (range 8–43) of the diameter.

Discussion: To our knowledge this is the first study systematically documenting the relation between hooks and the spinal canal in cadavers. No evidence of deformation of the spinal cord was found in this series of cadavers. The study shows, however, that particularly supralaminar hooks inserted in the cervical spine have a close anatomical relationship with the dura and also with the spinal cord. Close attention to detail and the use of other techniques at stenotic levels is therefore recommended.

43. Halo-vest treatment of odontoid fractures

K Halldin, B Lind, B Zoëga, A Nordwall

Department of Orthopaedics, Sahlgrenska University Hospital, Göteborg, Sweden

Treatment of odontoid fractures has always been controversial due to the high incidence of non-unions regardless treatment modality. This paper describes a consecutive series of halo-vest treated odontoid fractures.

Methods and materials: Between 1976 and 1996, 34 patients with odontoid fractures, 14 males and 20 females, were treated with halo-vest. Attention was given to reduce the fractures before the halo-vest was mounted. The fractures were almost equally divided into Anderson-d'Alonzo type II and III fractures. Age range was 9–89 years (mean: 51). Patients with associated skull-fractures or non-compliant were treated by primary open fixation or with collars. The patients were followed-up for at least 2 years. 5 patients died of other causes before the follow-up.

Results: All fractures healed but 2, both type II fractures, which gives an overall 94% healing rate. At the follow-up 50% of the patients were totally free of complaints, whereas 70% had decreased motion in axial rotation of the head compared to age and sex matched controls.

Conclusion: We have found, that halo-vest treatment in these fractures offers a safe alternative to surgery and leads to a high union rate with few complications.

Session 9: Knee arthroplasty

44. Difficult for solution hydroxyapatite coatings for titanium orthopaedic implants

Anatoly V Karlov¹, Vladimir I. Vereschchagin², Victor P Ignatov¹, Nataly G Romanenko²

¹The Centre of Orthopaedy and Medical Material Sciences of SB of RAMS Tomsk and ²The Tomsk Polytechnic University, Tomsk, Russia

Hydroxyapatite (HA) coatings on titanium orthopaedic implants fulfil some functions: 1) secure delivery calcium phosphates for bone tissue regeneration; 2) prevent penetration of titanium ions in organism; and 3) prevent titanium from participating in biological electrical processes. However, being in organism HA dissolves and velocity of this process depends on its density and crystallinity. Therefore in order to HA coating as long as possible fulfil its functions it is necessary to secure high adhesion strength with titanium, high density and high crystallinity.

Method: This problem is solved by method of plasma spraying coating. Powder for coating is made by means breaking up and selecting narrow fraction (60–80 mcm) of calcium phosphates as well as products of animals bones burning by 1,050 °C. Before using a powder was subjected to treatment removing a static charge from particles. The obtained powder is HA $\text{Ca}_5(\text{PO}_4)_3(\text{OH})$ (complete coincidence of X-ray reflexes by d and intensities d –2.81, –2.77, –2.72, –3.44, –1.84 Å) with traces of $\text{Ca}_3(\text{PO}_4)_2$.

Results: The obtained coating is crystalline homogenous layer with structure of HA with little increase of $\text{Ca}_3(\text{PO}_4)_2$ content and following parameters: Ca/P = 1.67–1.68; relative density 0.9; crystallinity 85–90%; adhesion strength 20 MPa and depth 100–500 mcm. Clinical tests show that it fulfil its functions during more than 3 years.

45. Bone quality in the proximal tibia and its relation to tibial component migration in total knee arthroplasty

Kjell G Nilsson and Mingguo Li

Dept. of Orthopaedics, University Hospital, Umeå, Sweden

The purpose of this study was to investigate the relation between the bone quality in the proximal tibia preoperatively and the magnitude and pattern of the tibial component migration postoperatively in a consecutive series of knees operated with TKA and where the mode of fixation was randomized..

Methods: 28 patients (18 women, 10 men, mean age 71 years) with gonarthrosis were operated with TKA. At the operation the mode of fixation was randomized, and 16 knees received uncemented and 12 knees cemented fixation..

Bone mineral density (BMD) in the proximal tibia was measured on DEXA scans obtained in the coronal plane within one week before operation. The accuracy of was de-

terminated having a coefficient of variation of 4.1 per cent. 3 regions of interest (ROI) with a height of 10 mm were positioned with their upper border 5 mm below the joint line in the healthy compartment of the knee so to include the bone where the tibial cut eventually was to be made at the operation. The average BMD of the proximal tibia was defined as the sum of these 3 ROI:s divided by 3.

Tibial component migration was measured using RSA postop., 6 weeks, and 12 months.

Results: 1. BMD: Mean average BMD was 0.81 g/cm². BMD in the medial and lateral condyles was influenced by the preoperative alignment of the knee, whereas the average BMD of the proximal tibia was influenced only by gender but not by the alignment. The knees were grouped into those having "soft" bone (BMD (0.81 g/cm²) and "hard" bone (BMD (0.81 g/cm²).

2. BMD and prosthesis migration: a. Uncemented fixation: 12 implants displayed migration whereas 4 were stable (3 with hard bone, 1 with soft bone). In knees with soft bone the entire tibial component subsided into the tibia, whereas in knees with hard bone the implants displayed a pattern of subsidence of one edge and lift-off at the opposite edge. In soft bone knees early subsidence was larger than in hard bone knees ($p < 0.05$), but after 6 weeks all implants in the soft bone group stabilized, whereas in the hard bone group subsidence and lift-off tended to increase up to 12 months ($p = 0.07$). In the knees with hard bone all implants subsided at the side of the knee with relatively higher BMD, whereas in the knees with soft bone the location of largest subsidence was evenly distributed between the sides with relatively harder and softer bone.

b. Cemented fixation: 9 implants displayed migration whereas 3 were stable (2 with hard bone, 1 with soft bone). All implants that were migrating displayed a pattern of subsidence of one edge and lift-off of the opposite edge. was rather equal between soft and hard bone. However, in both groups lift-off (but not subsidence) increased between 6 weeks and 12 months. In the knees with hard bone all implants subsided at the side of the knee with relatively lower BMD, whereas in the knees with soft bone the location of largest subsidence was evenly distributed between the sides with relatively harder and softer bone.

Conclusion: In uncemented fixation, early subsidence was larger in soft bone, but all components stabilized within 6 weeks, whereas in hard bone subsidence and lift-off was initially small but with no stabilization over time. Addition of bone cement to knees with soft bone diminished the early subsidence, but to the expense of the early stabilization. Addition of cement to knees with hard bone resulted in no improvement.

Some of the implants were stable irrespective the preop. bone quality, and subsidence did not always occur at the side of the knee with the softest bone. This implies that factors other than the bone quality such as the activity, the gait pattern, and the force distribution at the knee also are of importance.

46. Micromotion of cemented vs porous-coated tibial components with and without hydroxyapatite—a randomized radiostereometric study in 146 total knees

Åke S Carlsson, Ingemar Önsten, Anders Nordqvist and Jack Besjakov

Depts. of Orthopaedics and Radiology, Malmö University Hospital, S-205 02 Malmö, Sweden. Fax +46 40 336200

Radiostereometric analysis (RSA) was used to compare micromotion between three different types of tibial component fixation in a randomized series of 146 PFC total knee replacements. Hydroxyapatite-augmented porous-coating was compared both with porous coating and with cement fixation. Porous coating was compared with cement.

Results: Although there was no significant difference between the hydroxyapatite-augmented and the porous-coated components after two years, porous-coated implants migrated at a significantly higher rate ($p = 0.008$) between one and two years—a time interval which has been shown to be of predictive value. The best migration values were found in the group of cemented implants.

Conclusion: Whether hydroxyapatite-augmented porous-coating has any advantage over cemented fixation with respect to long-term durability of the tibial components in total knee replacement remains to be shown. The results found in our study do not point in such a direction.

47. The PCA Mk I total knee, clinical outcome 9–15 years after the index operation—a prospective observational study of 260 primary procedures

Anders Herrlin, Urban Lindgren

Karolinska Institutet, Dept. of Orthopaedics, Huddinge University Hospital, Huddinge, Sweden

The nonconstrained, posterior cruciate retaining, resurfacing anatomical total knee with porous coating to allow fixation without bone cement was introduced in the early 80:s as a solution to problems with loosening.

Materials: 70 % women, 174 OA and 86 RA. 149 noncemented OA, 50 noncemented RA. The cemented tibias were stemmed, the noncemented were two-pegged resurfacing. The choice of fixation was not randomised.

Results: The 10–11 years survival rate was 79.5 (72.7–86.4) % (mean (95% CI)) for the total cohort. Noncemented OA 75.3 (67.4–85.5)% and noncemented RA 75.4 (63.4–94.2)%. Of 51 aseptic revisions, there were 43 partial ; 8 tibia, 11 tibia + patella, 13 patella, 11 tibia polyethylene liner + patella, and 8 total (tibia+ patella + femur) revisions. The main reasons for revisions were loosening (22) and wear (17) and combinations of wear and loosening (10).

Conclusion: The PCA Mk I TKR included a number of design features which lead to a high revision rate for wear and loosening. Even if PE wear characteristics have been

improved in later designs, it is still the limiting factor for any implant survival in the active patient. Partial revision should be considered as a way of prolonging the lifespan of the implant. The survival analysis has to consider each component separately. The definition of failure should probably be more specified than to just the exchange of any component.

48. Early prospective changes in muscle strength after total knee arthroplasty

Jan S Lorentzen^{1,2}, Michael M Petersen^{1,3}, Christine Brof⁴, Ole R Madsen⁴

Depts. of Orthopedics ¹Hvidovre Hospital, ²Bispebjerg Hospital, and ³Rigshospitalet, and ⁴Rheumatology, Copenhagen Municipal Hospital, Denmark

Several authors have examined muscle strength in patients with arthrosis of the knee, but only few have evaluated prospective changes in muscle strength following total knee arthroplasty (TKA).

Material and methods: 30 patients operated on with insertion of either a cemented TKA (n 26) or an uncemented TKA (n 4) because of arthrosis were included in the study. Full weight-bearing from the first postoperative day was allowed in all patients, and they received standard postoperative physiotherapy. 1 week prior to surgery, and after 3 and 6 months, measurements of isokinetic and isometric muscle strength using a Cybex 6000 dynamometer were performed. After muscle strength testing the worst pain experienced during the tests was evaluated using a 0-10 point numerical rating scale.

Results: Isokinetic tests showed a bilateral, significant, and progressive increase in flexor muscle strength most pronounced in the operated legs (30–53%). Isokinetic extensor strength measurements showed significant increases in the operated legs (14–18%), while only a limited increase in extensor strength was observed in the healthy legs. Isometric flexor strength showed a significant decrease in the operated knees (17%), while in the healthy contralateral legs the strength remained unchanged. Isometric extensor strength showed a temporary decrease at 3 months, which had returned to the preoperative level 6 months postoperatively. No significant changes in strength were observed in the healthy legs. Knee pain level during the muscle strength measurements showed a significant decrease from the preoperative level.

Discussion: Following TKA isokinetic flexor and extensor strength increased while isometric strength decreased. Knee pain might be an important factor when muscle strength measurements are performed in KA.

Session 10: Childrens fracture and orthopedics

49. Delayed decision-making using ultrasound reduces the treatment rate in neonatal hip instability

Terje Terjesen¹, Ketil J Holen² and Agnar Tegnander²

¹The National Hospital, Oslo and ²Trondheim University Hospital, Trondheim, Norway

Most authorities advocate treatment start from birth of all babies with neonatal hip instability (NHI). The aim of this study was to evaluate delayed decision-making with regard to treatment.

Patients and methods: During a 2-year period, 99 newborns (1.5% of all live births) had NHI diagnosed on the first day after birth by experienced paediatricians. The unstable hips had a mean femoral head coverage (FHC) of 39% by ultrasound, implying that most of them were subluxated. No treatment was initiated but the neonates were re-examined at 1–2 weeks of age, at which time a decision regarding treatment was taken.

Results: At 1–2 weeks of age, 31 neonates had persisting hip instability and reduced FHC, and treatment with a Frejka pillow was started. The hips of the remaining 68 babies were clinically stable and their mean FHC had increased to 48% which is within the normal range. Treatment was therefore withheld. Further follow-up showed normal development in all hips that were treated and in all except 5 of the 68 untreated infants. These 5 infants had acetabular dysplasia with (n=1) or without (n=4) moderate subluxation at 4–5 months of age. They were treated with an abduction splint and their hips later developed normally.

Conclusion: Ultrasound was very useful in the decision-making of which hips that needed treatment. Our waiting attitude substantially reduced the treatment rate because spontaneous normalization occurred in more than half of the unstable hips. However, because a few infants developed hip dysplasia during the first months, a strict follow-up regime is essential in order to initiate treatment in these cases.

50. Chronic dislocation of the hip treated with femoral shortening osteotomy in patients with cerebral palsy

Terje Terjesen and Cato Hellum

Dept. of Orthopedics, The National Hospital, Oslo, Norway

Hip dislocation of several years duration in cerebral palsy needs treatment only if the patient has serious complaints. The aim of treatment is to reduce pain and problems with sitting function and perineal hygiene.

Patients and method: We have performed a shortening osteotomy of the femur in 15 patients (12 girls and 3 boys) with spastic quadriplegia or diplegia at an age of 14 (8–26)

years. The patients were severely mentally and physically retarded and only one patient had gait function with support. A subtrochanteric shortening osteotomy of 3–5 cm was performed and the osteotomy was stabilized with plate fixation. Twelve patients had unilateral osteotomy and 3 had bilateral. Postoperatively, a plaster cast keeping the legs in abduction was used for 6 weeks. The mean follow-up period was 5 (1–10) years.

Results: The symptomatic effect of the operation was good. The patients and parents were satisfied because the pain disappeared and they had less spasticity and stiffness. Complications were seen in 2 patients, who had skin necrosis under both heels caused by the plaster. Although reduction of the dislocation was not the aim of the surgery, radiographs at follow-up of 16 operated hips showed that 5 hips were reduced, whereas 5 were subluxated and 6 hips were dislocated.

Conclusion: We conclude that a shortening osteotomy of the femur has a good symptomatic effect in patients with CP, although most hips will remain subluxated or dislocated.

51. Synovitis in Legg-Calvé-Perthes' disease—evaluation with MR imaging in 84 hips

H Wingstrand¹, P Hochbergs², G Eckerwall¹, N Egund³ and K Jonsson²

¹Department of Orthopedics and ²Department of Diagnostic Radiology, University Hospital, Lund, Sweden and

³Department of Diagnostic Radiology, University Hospital, Aarhus, Denmark.

Purpose: To evaluate with MR imaging the degree and persistence of synovitis in the hip joint in LCPD.

Patients and methods: A total of 170 MR images in 72 patients (84 hips) with LCPD were examined. Serial T1 and T2-weighted MR images were obtained in the coronal plane to evaluate extent of the epiphyseal necrosis and the degree of synovitis in the joint. The classifications according to Catterall and Herring were established on contemporary conventional radiographs.

Results: MR revealed synovitis in all cases in the early phase of the disease. In Catterall group II, synovitis was discreet to moderate up to six months after diagnosis. Hips with more severe necrosis, Catterall group III and IV, had moderate to intense degrees of synovitis. Furthermore, there was a correlation between the degree of synovitis and the "lateral pillar" classification according to Herring. Also, there was a good correlation between the extent of signal changes in the epiphysis on MR imaging and the degree of synovitis. There was no difference when signal changes were evaluated on T1- or T2-weighted images.

Signs of synovitis could be seen up to 2,5 years after diagnosis in Catterall group I hips, in Catterall group II and III for up to 3 years. Some Catterall group IV hips had discrete or mild synovitis even 5 years after diagnosis.

Discussion: The degree of synovitis on MR imaging correlates with the extent of epiphyseal necrosis as well as to

the "lateral pillar" classification, i.e. to a poor clinical outcome. In Catterall group IV hips, synovitis even persists 5 years after diagnosis. Thus, we propose that anti-inflammatory medication should be discussed from a palliative and possibly also from a prognostic point of view.

52. A different view to the treatment of congenital dislocation of the hip by medial approach

S Sükrü Araç, Murat Bozkurt, Hakan Boya, Özal Özcan

Dokuz Eylül University Medical Faculty Department of Orthopaedics and Traumatology, Yzmir, Turkey

The treatment of congenital dislocation of the hip CDH remains one of the most demanding challenges in orthopaedics. In this study the result of our different technique of the early treatment CDH than the classical medial approach were reviewed.

Between June 1982 and March 1996, 54 hips in 36 patients who had CDH were treated by our different technique through a medial approach. The mean age at the time of the operation was 12 (4–16) months and the mean follow-up was 8 (1,5–15) years. 30 of the hips were in girls and 6 in boys. 29 were right hips and 25 left.

All patients had a reduction without capsulotomy and adductor and iliopsoas tenotomy through a medial approach. After reduction, the position of greatest stability within the safe zone was selected for cast immobilization. Casts were changed at the third month postoperatively, with control radiography. They usually were removed at the second three months period. In the follow up period no patients appeared to have avascular necrosis, redislocation and deep tissue infections.

We believe that there is no absolute necessity for the capsulotomy and clearing of acetabular structures in medial approach technique. We considered that our different technique is a safe and an effective method for the treatment of CDH.

In conclusion, in proper hips the usage of less traumatizing technique and a long period of cast application is feasible.

Session 11: Basic research

53. Proteoglycan turnover during development of spontaneous osteoarthritis in guinea pigs

L Wei¹, H Brismar¹, A Hjerpe², O Svensson¹

¹Division of Orthopaedics and ²Division of Pathology, Huddinge University Hospital, Karolinska Institute, S-141 86 Huddinge, Sweden

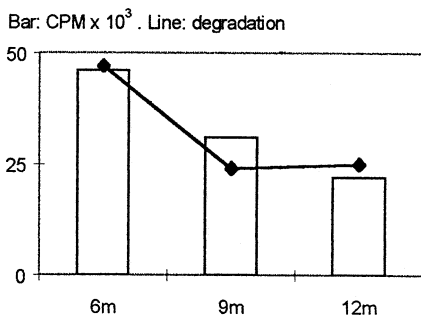
Spontaneous guinea pig knee osteoarthritis (OA) is a model system for studying primary OA. Proteoglycans (PGs) are vital for the mechanical properties of cartilage. Contents of PGs, in guinea pig tibial cartilage, vary regionally and is lower in OA cartilage (1). We studied the metabolism of PGs in relation to ageing and OA development.

Materials and methods: ³⁵S was injected intraperitoneally in 6, 9, and 12 months old Hartley guinea pigs. In each group three animals were killed after 24 hours and five after 7 days. Synthesis was defined as the amount of incorporated ³⁵S-PGs present after 24 h (CPM), and degradation as the elimination of ³⁵S-PGs from 24 h to 7 days after labeling.

Results: PG synthesis was highest at 6-months and on the medial side with its presumably higher load. The onset of OA was associated with decreased PG synthesis, while degradation of newly synthesized PG changed less.

Conclusion: The decrease in PG contents at onset of primary OA is the result of a slowly evolving process. The slightly negative metabolic balance is due to reduced synthesis with relatively unchanged degradation.

Reference: 1. Wei et al. Arthritis Rheumatism 1997; 40(11): 2075-2083.



54. Structural and biochemical changes in guinea pig osteoarthritis after surgically altered load

L Wei¹, H Brismar¹, A Hjerpe², and O Svensson¹

Dept. of ¹Orthopaedic Surgery, and ²Pathology, Karolinska Institute, Huddinge University Hospital, S-141 86 Huddinge, Sweden

Hartley guinea pigs spontaneously develop a knee arthropathy mimicking primary osteoarthritis (OA), predominately affecting the medial condyle (1, 2). The severity of the le-

sions can be influenced by surgically redistributing the load (3). Using this experimental model we studied the concentration of proteoglycan (PG) and collagen in OA articular cartilage.

Materials and methods: The load distribution on the tibia plateau of 9-month-old Hartley guinea pigs was modified by transtibial amputation or mid-femoral 30°-valgus osteotomy. At 12 months, the contents of PGs and collagen were studied in articular cartilage. Fibrillation index, i.e., the ratio between the adual joint surface and its smooth contour, was measured stereologically on the non-meniscus covered part of tibia condyle.

Results: An altered load affected the distribution and severity of OA. The severity of the lesions correlated closely to concentration of PGs. Increased load resulted in lower PG contents while higher contents was found in those with decreased load (Figure).

Conclusion: By varying the load it is possible to influence the severity of the developing OA. Fibrillation changes are correlated with biochemical changes of the cartilage matrix.

References: 1. De Bri et al. J Orthop Res 1995; 13: 769-76. 2. Wei et al. Arthritis Rheumatism 1997; 40(11): 2075-83. 3. Wei et al. Acta Scandinavica Othopaedica (in press).

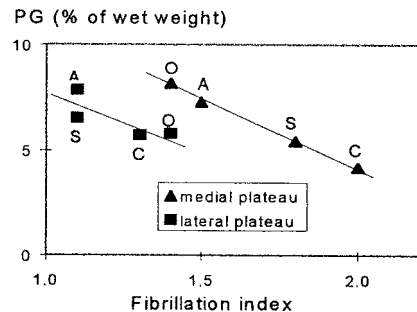


Figure. A amputation, O osteotomy, S sham operation, C contralateral side of amputation.

55. In vivo and in vitro strength retention of self-reinforced polyglycolide (SR-PGA) membrane

Vihonen Kimmo, Ashammakhi Nureddin, Mäkelä E Antero, Rokkanen Pentti, Kuisma Hannu and Törmälä Pertti

Depts. of Orthopaedics and Traumatology, and Surgery, Helsinki University Central Hospital, Helsinki, Finland, and Institute of Biomaterials, Tampere University of Technology, Tampere, Finland

The comparison of in vivo and in vitro strength retention of the self-reinforced polyglycolide (SR-PGA) membranes is presented.

Materials and methods: For in vivo study, SR-PGA membranes 0.15 mm thick and 15x20 and 15x40 mm size, were implanted in twenty-five Wistar rats' subcutis and around femoral bone, respectively. The rats were followed-up for 1,

2, 3, 6, 8, 15 and 30 weeks. For in vitro study, 15 SR-PGA membranes were excised and taken as specimens. The breaking force of the specimen membranes was tested using a tensile test machine.

Results: The initial tensile strength was 40 MPa. The tensile strength of specimens that were immersed in water declined as follows: 23 MPa after 1 week, 6 MPa after 2 weeks, 2 MPa after 3-4 weeks and 0,2 MPa after 5 weeks. The tensile strength of PGA membranes after subcutaneous implantation, was 11 MPa after 1 week, 1 MPa after 2 weeks, 0,3 after 3-6 weeks, 0,5 after 8 weeks and 0,7 after 15 weeks, while after implantation around femur it was: 7 MPa after 1 week, 0,3 MPa after 2-8 weeks and 1,6 MPa after 15 weeks. The membranes were absorbed totally, in rats, by 30 weeks. The SR-PGA membranes showed a faster loss of their strength in the beginning, in vivo than in vitro. The SR-PGA membranes lost their strength almost within 5 weeks, in vitro, while they retained it for 15 weeks in vivo.

Conclusions: The retention of strength in vivo for longer time is an important finding when considering application of SR-PGA for clinical purposes. This will be useaful for argu-mentation of comminuted bone fractures.

56. The effect of transforming growth factor-, released from a bioabsorbable self-reinforced polylactide pin, on a bone defect

Tielinen Laura,¹ Puolakkainen Pauli,¹ Pohjonen Timo,² Rautavuori Jorma,² Törmälä Pertti,² and Rokkanen Pentti¹

Depts. of ¹Orthopaedics and Traumatology, and Surgery, Helsinki University Central Hospital,¹ Helsinki, Finland, and ²Institute of Biomaterials, Tampere University of Technology, Tampere, Finland

Transforming growth factor beta 1 (TGF-) is a polypeptide growth factor which has been shown to increase bone formation in experimental animal studies.

Materials and methods: In this study TGF- was combined to a bioabsorbable poly-L/D-lactic acid fracture fixation pin. To assess the effect of TGF- on the healing of a bone defect filled with a Cellstick® viscose cellulose sponge (VCS). Serum samples were examined for TGF- with enzyme-linked immunosorbent assay (ELISA). After sacrifice radiographic and histologic studies were performed.

Results: At 3 and 6 weeks postoperatively there was an increase in fibroblast-rich mesenchymal tissue in the VCS in the test rats compared to the control rats. No difference in the amount of bone inside the VCS between the test and control rats was detected at any time point. ELISA did not show any difference between the test and control rats in the amount of TGF- in serum, indicating that it had been released locally.

Conclusions: The results suggest the feasibility of locally delivering TGF- by a biabsorbable fracture fixation device.

57. Osteogenic protein 1 enhances mechanical fixation of implants in trabecular bone

M Lind, S Overgaard, Y Song¹, SB Goodman¹, C Büniger, K Søballe

Orthopaedic Research Laboratory, University Hospital of Århus, Denmark. and ¹Dept of Orthopaedics, Stanford Universib Medical Center, USA

Introduction Osteogenic protein 1 (OP-1) also designated BMP-7 has previously shown extensive in vivo osteoinductive properties. However, little is known about the BMP's ability to enhance bony fixation of implants. The purpose of the present study was to determine if mechanical fixation of uncoated and hydroxyapatite coated implants could be enhanced by applying OP-1 in a collagen carrier in a critical sized 3 mm gap around the implants.

Methods: Cylindrical uncoated and hydroxyapatite coated titanium alloy implants (Ti6Al4V)(4x10 mm) with an edged surface texture were used in the study. The implants were inserted unloaded bilaterally into both the medial and lateral femoral condyles of 16 adult mongrel dogs. All implants were indially surrounded by a 3 mm gap. Eight dogs were included in each implant group. Three different test groups for each type of implantwere applied. 1) OP-1 device (325 ug OP-1 in 130 mg collagen matrix). 2) The collagen matrix without OP-1. 3) Empty gap. The OP-1 device and the collagen carrier was placed in the gap around the implants. The dogs were sacrificed after 6 weeks. After sacrifice, mechanical fixation of the implants were evaluated by push-out test of a 3.5 mm thick specimen on an Instron universal testing machine. Shear strength, shear stiffness and energy absorption was determined.

Results: All dogs completed the study. Mechanical testing showed that shear strength, stiffness and energy absorption were significantly increased for OP-1 stimulated groups. For uncoated titanium implants the OP-1 group demonstrated significant increased values above both control and collagen groups with respect to strength and stiffness, whereas for energy absorption OP-1 was only significantly different from the control group. For HA coated implants, the OP-1 group was significantly higher than both control and collagen groups with respect to stiffness, whereas for strength and energy absorption the OP-1 group was only significantly different from the control group. Improved bone ingrowth and bone volume was found for OP-1 device treated groups.

Discussion: The present study demonstrated that the addition of OP-1 device is capable of increasing mechanical fixation of both uncoated and HA coated implants. Interestingly the collagen matrix by itself demonstrated considerable stimulatory effect on fixation probably due to an osteoconductive effect, where the collagen matrix can capture stem-cells and other growth factors thatwill improve bone formation in the gap. These data are interesting for the use of OP-1 for stimulation of bony ingrowth in primary cementless endoprosthetic surgery.

58. Bone allograft, ProOsteon 200® and osteogenic protein-1 device® around noncemented implants

T B Jensen, S Overgaard, M Lind, O Rahbek, C Bünger, K Søballe

Orthopaedic Research Group, University Hospital of Aarhus, Denmark

Bone grafting is often the treatment of defects during revision of arthroplasties. We investigated, whether ProOsteon 200 (Interpore, Irvine, US) and OP-1 device (BMP-7) (Stryker Biotech) in different combinations enhances early mechanical fixation of implants. ProOsteon 200 is a granular porous hydroxyapatite bone substitute, OP-1 device is a bone growth factor with a collagen carrier which has been shown to improve bone ingrowth into implants, however not in combination with allograft and HA granules.

Methods and materials: 6 Labrador dogs had each 4 unloaded cylindrical hydroxyapatite coated implants inserted in the proximal humerus for 3 weeks. A 3 mm gap was left around each implant, which was filled according to the following treatment groups: Group 1: Allograft, group 2: Pro-Osteon, group 3:

Allograft+Pro-Osteon, group 4: Allograft + Pro-Osteon + OP-1-device. The amount of Pro-Osteon, OP-1 device and allograft was standardized by weight.

Statistics: Data are presented as mean values and standard error of mean. Unpaired t-test was applied, P-values less than 0.05 (two-tailed) were considered significant.

Results: Push-out testing showed a significant 300 % difference between group 3 and 4 in energy absorption (figure). Also, group 2 had significantly poorer mechanical properties compared to group 4. No significant differences between group 1 and 4 was found.

Conclusion: OP-1 device improved mechanical properties of group 3 by 300%, however, only energy absorption was significantly increased. ProOsteon alone was poor fixated indicating that this material should not be used alone. This study shows, that adding osteoconducting and osteoinducting materials to bone allograft might improve the mechanical properties of bone allograft.

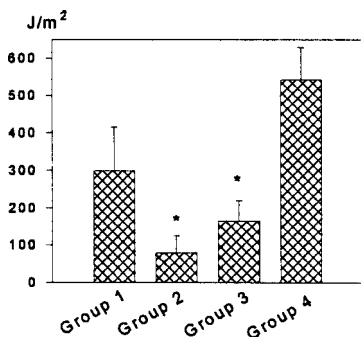


Figure. Energy absorption. * differs significantly from group 4.

Session 12: Spine

59. Autologous cancellous bone graft in lumbar spine fusions.

Michael B Nielsen, Lars Nimb, Jørgen H Hansen and Thomas Kier

Dept. of Orthopedics 3193, Rigshospitalet Copenhagen Denmark

A rabbit study was performed to make histological evaluation of bone formation following posterior spine fusion using autologous cancellous iliac crest bone graft.

Material and methods: Ten mature female white rabbits (4000–4500 g), underwent bilateral posterolateral lumbar spine fusion using standard surgical technique. A posterolateral fusion was performed at L5/6 and a decortication was done at L3/4 without grafting—as a sham operation. The animals were labeled with four different i.v. fluorochromes after 1, 2, 3 and 4 weeks running. They were killed after 5 weeks had the lumbar spine taken out, x-rayed and the two operated levels excised en bloc, and sagittally cut in halves. One half was embedded in methylmethacrylate and cut in a microtome for both usual van Gieson picrofuchsin/Stevenels blue histology and for unstained fluorescent-microscopic evaluation. The other half was decalcified, embedded in paraffin and sectioned for decalcified HE-stained specimens.

Results: Ten lumbar spines were included. One rabbit (the first) was only operated at one lumbar level with a facet-joint decortication and no bone grafting, and one rabbit had only 3 weeks of observation. Both animals were excluded from the study. Lightmicroscopic evaluation of the grafted group showed 7 out of 8 specimens with large amount of bone remodelling. In 6 of 8, areas of endochondral ossification was seen. In the ungrafted group we found no endochondral ossification and only a little amount of new bone formation. Fluorescence microscopy showed increasing bone formation during the five weeks of observation. Radiographic examination revealed 5 of 8 lumbar spines with good solid bone mass.

Conclusion: In the grafted specimens there was a larger amount of new bone formation and a more mature type with areas of endochondral bone formation compared to the ungrafted group.

This animal model proves very useable in comparing different types of graft materials and -techniques in lumbar spine surgery.

60. A non-linear finite element analysis of L4–L5

Christian Wong, Tron Darvann¹, P Martin Gehrchen and Thomas Kier

Spine Section, Department of Orthopaedics, National University Hospital of Copenhagen, Rigshospitalet, Blegdamsvej 9, DK-2100 Copenhagen, and ¹3D-Lab, School of Dentistry, University of Copenhagen, Nørre Allé 20, DK-2200 Copenhagen N, Denmark

The objective of this study has been to do non-linear Finite Element Method Analysis of L4-L5.

Material and methods: The FEA model was generated from CT images. The procedure of extraction consisted of 3 steps; (1) stacking by use of IDL software for (2) generation of 2D contours by the Mvox, software, and (3) finally creation of a 3D mesh by connecting the 2D contours.

The FEA model consisted of a central isotropic and linear volumic core of trabecular bone and incompressible nucleus pulposus surrounded by a shell of cortical bone and a multilaminar shell of annulus fibres, respectively. The ligaments and the facets were non-linear.

The method of validation was a comparison between the computed results and experimental data from compression tests and FEA results from literature, which were load-displacement behaviour, intradiscal pressure, disc bulge and facet load transfer for several relevant load cases.

Results: The FEA results were in general within 1 standard deviation of the experimental data. Generally, the results for disc bulge were lower than those of the experimental data. However, the computed FEA results showed the same pattern of behaviour as the experimental data in terms of a higher lateral disc bulge, becoming smaller posterior.

Conclusion: A 3-D non-linear finite element analysis model has been developed for L4-L5. The 3D FEA model was generated based on CT-scans. The FEA results for applied load cases have been verified, and confirm the reliability of the methodology.

61. Orthopaedic spine surgery-actual costs?

Mikkel Andersen, Niels Dieter Röck and Karsten Thomsen

Spine Unit, Dept. of Orthopaedic Surgery, University Hospital of Odense, Denmark

Few studies have specifically focused on the resource-demands of orthopaedic spinal surgery. In this study we compared the actual to the predicted costs when implementing spinal surgery.

Material and methods: During a 6 months period we prospectively recorded all costs in a consecutive series of all together 44 patients: Scoliosis (n=4), lumbar or lumbosacral instability (n=23), acute (8) or sequelae after (2) thoracolumbar fracture, spondylitis (3), or spinal stenosis (4).

We recorded the total costs of the treatment in each patient including preoperative evaluation, the hospital-stay, and the postoperative follow-up at the out-patient clinic. The recording included factors such as time consumption, price of implants, blood tests- and products, radiology, and utensils.

Results: The average costs could be predicted for implants (mean 20,406 DKr), length of hospital-stay (mean 12.5 days) and most other factors related to the treatment. On the other hand, some predictions were misjudged by a factor ten e.g. blood-products with an over-estimation of 450,000 DKr.

Conclusion: Orthopaedic spinal surgery is very resource-

demanding. Most costs could be predicted with high precision, but other turned out to be much lower than estimated.

62. Controversis in lumbar spine fusion—the role of pedicle screw fixation and 360° fusion—randomized prospective studies

Cody Bünger, S Eiskjær, E S Hansen, K Thomsen, K Høy, P Helmig, F B Christensen

Spine Section, Dept. of Orthopaedic Surgery, University Hospital of Aarhus, Denmark

The ultimate goal in lumbar fusion is a satisfied patient with solid fusion in a well balanced spinal segment without compression of neural elements. Unfortunately this goal is not always reached resulting in inferior functional outcome in 15–25% of lumbar spinal fusions. To improve fusion rates pedicle screw fixation and circumferential fusion have been introduced. A systematic evaluation of these components of lumbar fusion has been performed in two randomized clinical trials with the use of the Dallas Pain Questionnaire instruments.

Material and methods: Inclusion criteriae in both trials were severe chronic low back pain from spondylolisthesis grades I–II of from primary or secondary degenerative segmental instability. Age was between 20 and 70 years for the pedicle screw study and between 20 and 60 years for the circumferential fusion study.

130 patients were randomly allocated for no instrumentation (n=66) or CD instrumentation (n=64) in posterolateral lumbar fusion. In an ongoing study seventy-two patients have been allocated to combined anterior (Brantigan) and posterior (facet/pedicle screws) (n=35) or posterolateral fusion with titanium CCD.

There was no significant difference between the two groups except for a significant (p<0.05) better daily activity level in the instrumented group, when neural decompression had been performed. The global patient satisfaction was 82% in the instrumented group versus 74% in the posterolateral fusion with titanium CCD (n=37). Variables were registered preoperatively and at 1 and 2 years postoperatively in both studies.

Results: Pedicle screw study: A 97.7% two-year follow-up was achieved. Fusion rates deduced from plain radiographs by independant observers were not significantly different between instrumented and not instrumented posterolateral lumbar fusion. There was no difference in short (fused segment) and long (L1–S1) lordotic angle between the groups. The functional outcome score improved significantly in both groups from preop to one year postop within the categories of daily activities (p<0.01), work/leisure activities (p<0.01), anxiety/depression (p<0.05) and social interest (p<0.05), whereas no significant change was found from one year to two year postop. Independant observers were not significantly different between instrumented and not instrumented posterolateral lumbar fusion. Instrumentation increased both operation time, blood loss and early

complication rate significantly. Significant symptoms from misplaced pedicle screws were seen 4.8% of instrumented patients. Reoperation rate was 15% in instrumented versus 6% in noninstrumented group ($p < 0.01$).

Circumferential lumbar fusion study: The preliminary results indicate that operation time is significantly longer 316 min (200-480) in 360 degree fusion group versus 210 min (90-420) in the CCD titanium group. Blood loss is not significantly different: 1245 (300-4500) mL versus 1190 (300-2700) mL, respectively. Complication rates include at present 2 nerve root lesions and one mechanical failure in the posterolateral fusion group versus one neural lesion and one iliac vein laceration in the circumferential group. Very preliminary results demonstrate superior functional outcome in circumferential fusion group as well as improved lordotic correction with anterior instrumentation.

Conclusion: The results from these randomized prospective studies do not justify the use of pedicle screws alone as an adjunct to posterolateral lumbar fusion. However, preliminary results might indicate that superior functional outcome can be achieved by use of circumferential fusion with anterior or interbody fusion combined with posterior screw fixation in compression.

63. Evaluation of the three column theory using finite element analysis method

Christian Wong, P. Martin Gehrchen and Thomas Kjaer

Spine Section, Department of Orthopaedics Surgery, National University Hospital of Copenhagen, Rigshospitalet, Blegdamsvej 9, DK-2100 Copenhagen, Denmark

The main objective of this study was to evaluate the Three Column Theory (1) using Finite Element Method Analysis (FEA) of the Thoraco-Lumbar Spine.

Material and methods: The FEA model of T12-L2 was generated from CT images. The FEA model consisted of a central isotropic core of linear 4-node three dimensional tetrahedral solid elements of trabecular bone and an incompressible nucleus pulposus surrounded by a shell of cortical bone and a multilaminar shell of annulus fibres, respectively. The facets and the ligaments were defined as displacements and 2-node uniaxial truss elements active in tension only, respectively.

The evaluation was performed as a comparison between results of an intact FEA model and of FEA models with 1 to 3 column instability and a burst fracture with 50 % body involvement. Load-displacement behaviour and disc bulge for axial compression, flexion, extension and lateral bending load cases were tested.

Results: Generally, the results in all the load cases* showed the same pattern of behaviour with a marked increase in displacement and posterior and posteolateral disc bulge for a two and three column instability compared to a single column lesion. In flexion** the burst fracture had a marked increase in posterior displacement, and posterior and posteolateral disc bulge compared to the intact model. The

instability increased from 31-144%.

Comparison of fracture types	Displacement	Upper disc bulge
Two vs. one instability	31% *	71% *
Three vs. one instability	134% *	233% *
Burst vs. intact	144% **	262% **

Conclusion: The FEA Fracture model of the Thoraco-Lumbar Spine showed an increase of instability from 31 % to 262 % for the two and three column lesion, and for burst fractures in flexion. This was in accordance with the classification based on a retrospective study by Denis (1).

Reference: 1. 'The Three Column Spine and Its Significance in the Classification of Acute Thoracolumbar Spinal Injuries'. Denis; 8, 8, 1983, Spine; s817-831.

Acknowledgments: Tron Darvann, 3D-Lab, School of Dentistry, University of Copenhagen.

64. Laparoscopic lower lumbar spine fusion, indications and preliminary results

Thomas Kjaer, Peter Blyme, Benny Dahl and P Martin Gehrchen

Rigshospitalet, Copenhagen, Denmark

Minimal invasive surgery offers several advantages compared to open conventional techniques. In lumbar spine fusion it is hypothetically possible to avoid some of the several devastating effects of conventional open surgery. However, it is still to be documented that the long-term results of minimal invasive techniques are superior. This study evaluates the technically problems encountered in an initial series of patients treated with lower lumbar fusion with a laparoscopic technique using cages and the preliminary results.

25 patients were included, 13 women and 12 men, median age 41. Fifteen were operated on for degenerative motion segment disease, 10 for grade 1 spondylolisthesis. In all cases except one an anterior laparoscopic technique with fusion cages were used. 19 were fused at the L5-S1 level, 5 at the L4-L5 level and 1 at the L2-L3 level using retroperitoneal approach. Significant peroperative complications were not seen and no conversion to open technique was necessary. The average operation time decreased from 4 h 40m to 2 h. One patient was explored the first postoperative day because of bleeding from one of the abdominal wall ports. Another patient had one cage removed after two days because of entrapment of the L5 root. The rest had an uncomplicated perioperative course.

Results: 19 patients were available with a median follow up of 15 months, 4 had too short follow up period. One died later due to DVT and pulmonary embolism. In two cases a supplementary posterior fusion were performed because of suspicion of instability at the level operated on. Excluding these and patients with initial technical complications, 15 could be evaluated for initial result. Of these 11 (73%) had a

good result with no residual symptoms or only minor discomfort. Postoperative radiographic evaluation showed no loosening except for the two cases supplemented with posterior fusion.

Conclusion: This new technique has been introduced with an acceptable rate of perioperative complications. The initial outcome seems good and justifies further activity and development of this method.

Session 13: Childrens fracture and orthopedics

65. Transposition of the apophysis of the greater trochanter for reconstruction of the femoral head after neonatal septic arthritis of the hip—a 2–11-years follow up.

Pål Benum

Orthopaedic Department, University of Science and Technology Faculty of Medicine, Trondheim, Norway.

A method for reconstruction of the femoral head in dislocated hips following femoral head necrosis after neonatal septic arthritis has previously been described (Benum 1992). The aim of this paper is to present the results of this procedure 2–11 years postoperatively.

Patients and methods: Four patients were operated on at the age of one to 6 years. The hip joint was opened through an anterior approach and a subtrochanteric osteotomy was performed. The cartilage of the apophysis of the greater trochanter was trimmed after resection of the gluteal tendons. After reduction of the apophysis to the acetabulum the osteotomy was fixed in varus position with Steinmann pins or a plate. The resected gluteal tendons were then sutured distal to the osteotomy. A spica cast was applied for 2–3 months.

Results: Radiographic follow up revealed the development of an ossification center in all the new femoral heads. The size of this center gradually increased and a nearly hemispheric head congruent to the acetabulum developed. An almost normal joint space was seen in two hips observed for 8 and 11 years, respectively. In all patients the operated hip was stable and the walking function was significantly improved. A good mobility was found in all the hips, except one with only two years follow up. *Conclusions:* The presented method gave good clinical and radiological results up to 8 and 11 years postoperatively.

References: Benum P. Acta Orthop Scand 1992; 63 (Suppl 248): 108.

66. General or selective ultrasound screening of the hip joints in newborns—a prospective, controlled randomized study of 15,529 newborns

Ketil Jarl Holen, Agnar Tegnander, Terje Terjesen, Tobias Bredland, Sturla H Eik-Nes¹

Depts. of Orthopedic Surgery and ¹Obstetrics and Gynaecology, Trondheim University Hospital, N-7006 Trondheim, Norway

Patients and methods: To evaluate the effect of ultrasonographic screening of the hip joints in newborns, we started a prospective, controlled randomized study in January 1988. During a 5-year period 15,529 newborns were randomized to either clinical screening only or to ultrasound examination

of the hip joints in addition to the clinical screening. Newborns randomized to clinical examination, but with well-known risk-factors for hip dysplasia (HD), were also examined by ultrasound. The effect of the screening was measured as the number of late presenting cases of HD in the 2 groups during the study period and an additional observation time of 4 years.

Results: The 2 randomized groups were identical concerning number of infants, sex, birth weight, birth length, birth rank and risk-factors for HD. The number of late presenting cases of HD have been dramatically reduced during the study. One case (0.1 per 1000) of late HD have been discovered in the ultrasound group, whereas 5 cases (0.6 per 1000) of late HD have been discovered in the group with only clinical screening. The difference between the 2 groups in late presenting cases of HD is not statistically significant.

Conclusions: We conclude that when the clinical screening is optimal, the effect of an additional ultrasound examination measured in late presenting cases of HD is marginal, and therefore not necessary. We recommend that ultrasound examination then is offered newborns with risk-factors for HD.

lower failure rate, but a higher risk of AVN. Therefore, we still recommend the Frejka pillow when treatment is started within few days after birth.

67. Good results after treatment with the Frejka pillow for neonatal hip instability—a 3–6-year follow-up study

Agnar Tegnander, Ketil Jarl Holen, Svein Anda¹, and Terje Terjesen

Depts. of Orthopedics and ¹Radiology, Trondheim University Hospital, Trondheim, Norway

Because there is no consensus with regard to the efficiency of the Frejka pillow in treatment of neonatal hip instability (NHI), the aim of the present study was to evaluate our results with this device.

Patients and methods: During the 3-year period 1988-90, the Frejka pillow was used in 108 newborns with clinical NHI verified by ultrasonography. Treatment lasted 4 months. At an age of 3–6 years, 85 of the children attended a follow-up examination with clinical examination and roentgenography.

Results: There were 3 treatment failures (2.8%), defined as infants who needed additional treatment with an abduction splint some months later. Avascular necrosis (AVN) of the femoral head occurred in one of these patients (0.9%).

At the latest follow-up, intoeing gait was observed in 17% and slightly reduced hip mobility in 20% of the patients. As compared with normal children, the patients with previous NHI had somewhat reduced coverage of the femoral head by radiography, indicated by a lower center-edge angle and a higher migration percentage. The anteversion (AV) angle was larger than that of normal children but only 3 patients had abnormally high AV angles.

Conclusion: The results with the Frejka pillow were good, with few treatment failures and complications. More rigid devices like the von Rosen splint seem to involve a slightly

Session 20: Hip fracture

68. Femoral neck geometry as a predictor of hip fracture

Olof Johnell, Magnus Karlsson, Ingemar Sernbo, Karl Obrant, Inga Redlund-Johnell

Dept. of Orthopaedics, Malmö University Hospital, Malmö, Sweden

One of the primary determinants of bone strength is bone mass and several studies have shown that bone tissue strength is proportional to bone mineral density (BMD). Bone mass is not the only predictive factor for a future hip fracture, as both bone mass and hip fracture incidence are lower in Japan as compared with Sweden or France. The following study was done to evaluate if geometrical conditions in the hip are associated with hip fracture incidence.

Material and methods: Hip geometry (hip axis length, angle femoral neck-femoral shaft, femoral neck width, femoral shaft width, pelvis width) was measured on plane radiographs and on DEXA-scans (dual energy X-ray absorptiometry). 125 hip fracture patients, 33 men (76 ± 10 years) and 92 women (78 ± 9 years) were compared with 192 DEXA controls (92 men and 100 women) and 163 radiographic controls (70 men and 93 women). The DEXA controls were chosen from our large file of normative data and the radiographic controls were chosen where radiographs were undertaken due to minor trauma without fractures or due to unspecific hip pain without obvious concomitant disease of the hip.

Results: We found indications of a wider skeleton in both male and female hip fracture patients as compared with controls. No indications were found of a difference in the hip axis length or a difference in neck-shaft angle in fracture patients as compared with controls.

Conclusion: We could not verify findings in other studies of an increased hip axis length in hip fracture patients as compared with controls.

69. Nail or arthroplasty—a randomised study of displaced, cervical hip fractures

Cecilia Rogmark, Olof Johnell, Ingemar Sernbo

Dept. of Orthopaedics, Malmö General Hospital, Malmö, Sweden

In surgical treatment of displaced, cervical hip fractures osteosynthesis or arthroplasty are the main alternatives. The method of choice in Scandinavia have been osteosynthesis. The aim of this study is to compare the two methods regarding complications, mortality, functional outcome etc.

Material: 1995–1997, 440 patients aged 70 and older with hip fractures graded Garden 3–4 were included in a 2-year prospective multicenter study consisting of twelve hospitals in the south of Sweden. Patients with mental confusion or rheumatoid arthritis were excluded, as well as bedridden

or institution dwelling persons. The patients were randomised to either osteosynthesis or arthroplasty.

Results: Preliminary 4-months results shows that patients given arthroplasties have better walking ability and less pain, compared to the group with internal fixation ($p < 0.001$). 22% of the internally fixated patients were reoperated, compared to 10% of those with arthroplasties ($p = 0.006$). 27% in the “nail group” were considered failures, compared to 3% in the arthroplasty group ($p < 0.001$). There were no difference in mortality or morbidity.

70. A biomechanical comparison of the Medoff sliding plate and a standard sliding hip screw for fixation of unstable intertrochanteric hip fractures

Ola Olsson¹, Frederick J Kummer², Leif Ceder¹, Kenneth J Koval², Sune Larsson³, Joseph D Zuckerman²

Depts. of ¹Orthopedics, Helsingborg Hospital, Helsingborg, Sweden, ²Orthopaedic Surgery and Bioengineering, Hospital for Joint Diseases Orthopaedic Institute, New York, USA, and ³Orthopedics, Uppsala University Hospital, Uppsala, Sweden

The Medoff sliding plate provides a dual sliding capability along both the femoral shaft and neck to theoretically increase interfragmentary compression and load-sharing in trochanteric hip fractures. We studied intertrochanteric fracture fixation in cadaveric bone to determine if this device has a biomechanical advantage in comparison to a standard sliding hip screw.

Materials and methods: In 12 cadaver femurs intertrochanteric fractures were created and during sequential destabilization bone and plate strains and fragment displacements were determined as a function of applied physiological loads before and after short-term cycling.

Results: The Medoff sliding plate produced a mean higher medial cortex strain than the sliding hip screw in all fracture models and at all loading levels. There were no significant differences in plate strains, fracture displacements or load to failure between the 2 devices.

Conclusion: These observations favour the dual sliding principle in terms of providing fracture compression and load-sharing, which may explain low failure rates in clinical series of unstable intertrochanteric fractures treated with the Medoff sliding plate.

71. Gotfried PC.C.P—a new method for osteosynthesis of intertrochanteric fractures of the femur

Michael Krasheninnikoff, Jens Gramkow, Carsten Tørholm

Dept. of Orthopedic Surgery T, Gentofte Hospital, University of Copenhagen, Denmark

Gotfried PC.C.P. Percutaneous Compression Plating, is a new method for treating intertrochanteric fractures using two sliding screws and compression plate.

The advantages of the method over conventional methods should be :

- Percutaneous technique (lesser surgical trauma).
- Preserving the lateral wall of the trochanteric area and thus reducing the risk of deteriorating the nature of the fracture during surgery.
- Provides lateral support to prevent collapse of the fracture before healing has occurred.

We describe the method and present our results in 30 cases.

Material : Two surgeons were trained in using the method by the designer of the system, Dr. Y. Gotfried. All patients with intertrochanteric fractures admitted to the department between 13 Sept. 1997 and 12 Jan. 1998 were treated with the PC.C.P if it was possible for one of these two surgeons to perform the surgery. There were 10 two-fragmentary fractures, 2 three-fragmentary fractures, 8 four-fragmentary fractures and 10 multifragmentary fractures. Eleven men and 19 women was included. Median age were 87 years (range 61-95). The first 22 patients have been followed for at least 6 weeks and the first 14 patients for at least 12 weeks. Eight of the 30 patients had died within 6 weeks after fracture, leaving 22 patients for follow-up.

Results: All fractures in patients seen at the 12-week follow-up had healed. We did not observe any re-displacement of the fractures in the first 22 patients seen at the 6-week follow up. One patient had one screw penetrating the femoral head due to poor positioning during surgery. This patient eventually died of causes not related to the operation. One patient had a soft tissue revision due to haematoma.

Conclusion: We find the Gotfried PC.C.P easy to use and the PC.C.P might have some advantages over other systems for osteosynthesis of intertrochanteric fractures. We find that the Gotfried PC.C.P deserves further investigation.

72. Changes in soft tissue body composition during treatment with anabolic steroids in women with hip fractures—a prospective randomized study on 64 female patients

Margareta Hedstrom¹, Kerstin Sjoberg², Eva Brosjö³, Kent Åstrom¹ and Nils Dalen¹

Departments of ¹Orthopaedics, ²Geriatrics and ³Radiology, Karolinska Institute, Danderyd Hospital, S-181-88 Danderyd, Sweden

Patients with hip fractures lose muscle and bone mass postoperatively, at least during the first six months. The aim of the study was to investigate if Deca Durabol, an anabolic steroid given postoperatively, could reduce the loss of muscle and bone mass and thereby affect the rehabilitation period.

Patients and methods: 64 women operated on for a hip fracture were randomly allocated to a one year treatment

with either anabolic steroids (Nandronol 25 mg i.m. every third week), vitamin D (alfacalcidol 0.25 ug) and calcium (500 mg) or calcium only. The patients came from their own homes and were over 65 years of age. Body mass index (BMI) were normal with no differences between the groups. The volumes of the thigh muscle were measured with quantitative computer tomography (QCT), before treatment, after 6 and 12 months. Triceps scinfold thickness (TSF), reflecting subcutaneous fat mass, was measured with a caliper in the middle and the back of the right upper arm at the same time intervals as above.

Results: During treatment with anabolic steroids, vitamin D and calcium, the thigh muscle volumes increased in both the operated and the contralateral leg, compared with the group which received calcium only. TSF decreased significantly more in the patients treated with anabolic steroids.

Conclusion: Anabolic steroids, influenced muscle and fat mass in this group of patients postoperatively, even with this moderate dose. If there are further advantages, such as reduced losses of bone mass, it is still to be analysed.

73. Internal fixation or arthroplasty for displaced intracapsular fracture in the elderly—a randomised trial

Martyn J Parker

Orthopaedic Department, Peterborough District Hospital, Thorpe Road, Peterborough PE3 6DA. England

The displaced intracapsular fracture has been termed the 'unsolved' fracture as clinicians are unsure as whether the femoral head should be preserved or replaced.

Patient and methods: 200 patients aged over 70 years with a displaced intracapsular fracture, were entered into a prospective randomised trial. Treatment was either an uncemented Austin Moore hemiarthroplasty or internal fixation with 3 parallel screws. All surviving patients were followed up for a minimum of two years.

Results: Internal fixation resulted in a reduced operative time, operative blood loss and transfusion requirements. There was on significant differences in the cost of treatment or length of hospital stay. Internal fixation was associated with an increased readmission and re-operation rate but a tendency to a lower mortality. Functional assessment of the survivors at one year from injury showed no significant difference between the two groups.

Conclusions: Arthroplasty is associated with a reduced re-operation rate but at the expense on an increased mortality.

74. Incidence of fixation failure following Sliding Hip Screw fixation of 1000 extracapsular femoral fractures

Martyn J Parker

Orthopaedic Department, Peterborough District Hospital, Thorpe Road, Peterborough PE3 6DA. England.

Patients and methods: A consecutive series of 1,000 patients with an extracapsular hip fracture treated using a Sliding Hip Screw (SHS), were prospectively studied to determine the incidence and cause of surgical complications on a large series of patients.

Results: There were 57 cases (5.8%) of technical failure of fixation and 8 cases (0.9%) of deep wound sepsis. Cut-out of the DHS was the commonest of fixation failure occurring in 39 cases, it was associated with varus reduction of the fracture, posterior/ superior placement of the lag screw, comminution of the lateral femoral cortex and medialisation of the distal fragment. Other types of failure were detachment of the plate from the femur (6 cases), re-fracture around the implant (4 cases) and non-union (2 cases).

Conclusions: The majority of fixation failures could be accounted for by errors of surgical technique, particular inadequate reduction of the fracture and incorrect placement of the lag screw.

75. 10-year results of the Peterborough hip fracture project

Martyn J Parker, Glyn A Pryor

Dept. of Orthopaedic Surgery, Peterborough District Hospital, Peterborough PE3 6DA, England

Since its inception in 1987 the Peterborough Hip Fracture project has designated specific resources and staff to the treatment of hip fracture patients. Patients are managed according to defined protocols which include early surgery followed by early supported discharge whenever possible.

Results: To date 2,560 patients have been treated under the scheme. The peri-operative mortality has fallen from 21–5%. The average total hospital stay has been reduced from 51–21 days whilst the proportion of patients discharged home directly from the orthopaedic ward has increased from 58–85%. Transfer of patients to geriatric wards has been reduced from 31–11%. For patients operated on under the scheme the incidence of major surgical complications has been reduced from 13–5% with the re-operation rate reduced from 8–4%.

Conclusions: These results indicate that the development of designated staff and treatment regimes for this group of patients has substantial benefits and should be encouraged.

Session 21: Upper extremity

76. Magnetic resonance imaging (MRI) for occult scaphoid fractures

Shirzad Houshian¹, Per Riegels-Nielsen¹, Susanne Rosbach² and Steen Lindequist²

Depts. of ¹Orthopedic and ²Radiology, Esbjerg County Hospital, Esbjerg, Denmark

The aim of the study was to evaluate the accuracy of MRI in diagnosing of occult scaphoid fractures in clinically unclear situation and to demonstrate additional lesions of the wrist.

Material and methods: From January to March 1997, 20 patients (13 male, 7 female) with a clinically suspected scaphoid fracture were included in this prospective study. All of the 20 patients had sustained a wrist injury and complained about pain at the anatomical snuff box. All of them were treated to our usual treatment procedures.

Results:

Type of injury	Radiography	MRI
1) Scaphoid fracture	2	3
2) Distal radius fracture	0	2
3) Fracture of 2. Metacarp	1	1
4) Fracture of capitatum	0	1
5) Bone contusion	0	3
6) Soft tissue contusion	0	15
7) Lesion of triangular disc	0	2

Conclusion: In cases of wrist injuries with clinically suspected fracture of the scaphoid MRI are superior to conventional radiography for proper diagnostics. This procedure may prevent patients with simple wrist sprains from being immobilized for weeks and thus save money in our health system.

77. Incidence of scaphoid fractures in Malmö—comparison between the 1950's and the 1990's

Brynjólfur Jónsson¹, Henrik Dütte², Inga Redlund-Johnell³, Olof Johnell²

Depts. of ¹Surgery Akranes Hospital, 300 Akranes, Iceland, ²Orthopedics and ³Diagnostic Radiology, Malmö University Hospital, 205 02 Malmö Sweden

During the century changes in the incidence of fractures has been found. This applies mainly to fragility fractures such as the hip and wrist.

The purpose of this study was to examine the incidence of fractures in the scaphoid bone of the wrist.

Material and methods: At our Department of Radiology all films and records have been saved during the century. All films taken of the wrist region were examined and fresh fractures of the scaphoid bone were registered. The periods of 1953–1957 and 1991–1992 were selected.

Results: During 1953–1957, 150 fractures were found and

134 during 1991–1992. There were three times as many fractures in men. In the 1950's the incidence among men was 4/10.000 residents in age groups 10–39 and declined thereafter. For women the incidence was 1/10.000 in age groups 10–19 and after 50.

In the 1990's the incidence among men increased to 7–11/10.000 in age groups 10–39. For women an increased incidence with a bimodal distribution of higher incidence in age groups 10–19 and after 60 was found. The changes in incidence between the periods were not statistically significant.

Conclusion: A slight non-significant increase in incidence was found during the 1990's. There is probably a gender different causes of fractures. In men fractures occur mostly in the young. In women the bimodal distribution is probably due to osteoporosis in the elderly.

78. Neer hemiarthroplasty for displaced humeral head fractures

Claus Hjorth Jensen, Majed Haddad, Sten Rasmussen and Stephen Rofail¹

Departments of Orthopaedic Surgery, Hvidovre University Hospital, Copenhagen, Denmark and ¹North Tyneside Health Care NHS Trust, North Tyneside General Hospital, North Shields, Tyne & Wear, U.K.

Comminuted fractures of the humeral head may be complicated by avascular necrosis. Consequently we have opted for prosthetic replacement in a subgroup of fractures in patients able to cope with the subsequent rehabilitation. The aim of this study is to present the 3-year follow up on Neer hemiarthroplasty in the treatment of displaced humeral head fractures.

Material and methods: From 1992 to 1995 a total of 29 patients were treated with cemented Neer hemiarthroplasty for displaced humeral head fractures. Twenty-four cases were four-fragment fractures whereas the remaining cases were three-fragment fracture dislocations. The median age at the time of injury was 75 (54–86) year, 23 were women. A standard deltopectoral approach was used. Operation was performed median 2 (1–28) days after injury. Physiotherapy was commenced 7 (1–14) days after surgery. No surgical complications were encountered.

25 patients were assessed at follow up 3 (2–5) years after injury, as 4 patients had died from unrelated causes. The Constant score comparing the shoulder in question with the contralateral was used to assess the clinical outcome. Pain and activity were further assessed on a 100 mm VAS and a questionnaire on nine ADL tasks (maximum 27 points) respectively. Standard radiographic evaluation was performed. Non-parametric statistical methods were used.

Results: Median Constant score of the operated shoulder was 52 (17–98) compared to 79 (47–100) of the contralateral shoulder ($p < 0.01$). The median pain score was 15 mm (0–66). The ability to perform ADL amounted to 15 (0–27) points. Delay of operation was adversely related to Constant score ($p < 0.01$), pain ($p < 0.05$) and activity ($p < 0.05$), whereas

postponement of physiotherapy had no impact on outcome. No radiographic signs of loosening were found.

Conclusion: The severely reduced range of motion and inability to perform ADL particularly influenced the low Constant score. Pain appeared to be only a minor problem as the VAS-score was low.

The Neer hemiarthroplasty yields reliable results in the treatment of dislocated humeral head fractures as far as pain and longevity is concerned. However, the ability to perform activities of daily living and range of movement is severely hampered. Operation should not be unduly delayed.

79. The effects of isokinetic muscular activity on pressure in the supraspinatus muscle and shoulder torque

Håkan Sporrang, Jorma Styf

Dept. of Orthopaedics, University of Göteborg, Sahlgrenska University Hospital/ Östra, Göteborg, Sweden

Pressure (IMP) in the supraspinatus muscle during contraction may increase to levels that impede muscle blood flow. This might increase the risk of tendinitis. The effects of eccentric and concentric activity on IMP is, however, not known.

Material and methods: Pressure in the supraspinatus muscle, EMG and shoulder torque during isokinetic muscular activity (contraction velocity 60°/sec, on a computerized ergometer) were measured continuously in 9 healthy subjects. The ROM was between 0 and 120° of abduction. Figures are given as mean values and one standard deviation (SD).

Results: Mean IMP and peak IMP during concentric and eccentric muscular activity did not differ significantly, but the peak values were reached at different arm positions. The mean torque was significantly higher during eccentric activity, but the quota between IMP and torque (mmHg/Nm) was significantly higher during concentric activity.

Conclusion: The supraspinatus muscle is heavily loaded not only in high arm positions, but also during eccentric activity in arm positions of 0°–30° of abduction.

Table 1. Joint angle at peak IMP and joint angle at peak torque, SD

	IMP mmHg	Abduction degrees	Torque Nm	Abduction degrees
Concentric	135 57	115 15	40 12	44 30
Eccentric	134 60	6 7	55 8	74 14
p-value	n.s.	< 0.001	< 0.02	< 0.05

Table 2. Mean values and SD and one standard deviation of six parameters during the full range of motion (0°–120°)

	IMP mmHg	Torque Nm	IMP/Torque mmHg/Nm	EMG µV	EMG/Torque µV/Nm	Work J
Concentric	96 29	35 2.3	3.0 1.1	1045 208	31 6.8	73 27
Eccentric	97 26	46 6.1	2.3 0.5	917 287	21 7.2	98 33
p-value	n.s.	< 0.001	< 0.05	n.s.	< 0.02	n.s.

80. Presentation of a new dynamic external fixator for fractures of the distal radius

Leiv M Hove, Per Helland, Anders Mølster

Dept. of Orthopaedics, Haukeland University Hospital, Bergen, Norway.

We have developed a new, dynamic, external fixator for distal radius fractures. The fixator and the results from the first study will be presented.

Material and methods: The rationale for the design of the device was to construct a flexible distractor through which dynamic traction is applied to the fracture. The dynamic traction is maintained during flexion and extension as well as radial and ulnar deviation. This was achieved by a combination of distraction and compression forces where a distraction spring near the bone acts as a fulcrum.

In order to develop the design, a preliminary flexible fixator was constructed and applied to anatomical specimens. Based on these experiences a first device was constructed and operations on 18 volunteers with unstable fractures were performed. Several modifications of the prototype were made during this preliminary series.

The modified prototype of the new device was now used for a first study: 30 fractures in 30 patients were included in this prospective series. The median (range) age of these patients were 60 (33–78) years, 23 patients were female, 9 fractures were classified (AO/ASIF) as type A3, 1 type C1, 15 type C2, and 5 type C3. The device was left open to allow full range of motion of the wrist from the first day. The device was removed after median 6 (3–9) weeks.

Results: At final follow-up the median radial shortening was 0 (0–5) mm, the volar angulation 7°, and the radial inclination 24° (16–30). Twenty-four patients had no radial shortening during the flexible fixation period, 4 had <3 mm, 20 patients had unchanged and 8 had improved the radial tilt. At removal of the fixator the flexion/extension was 54°, at 12 weeks 88°, and at 6 months 104°. Supination/pronation at 6 weeks was 113°, at 12 weeks 166°, and at 6 months 176°. Four patients had complications: 2 had temporary dystrophy, one man (150 kg) lost 5 mm radial length, probably because of too week distraction forces, and one lost 4 mm because too early (3 weeks) removal of the fixator.

Conclusion: This new dynamic fixator shows promising results. An ongoing randomised study must be fulfilled before the fixator is ready for general use.

Session 22: Primary and revision arthroplasty

81. Abnormal wear pattern in the hydroxyapatite-coated Dual Radius socket (PSL)

Thord von Schewelov, Åke S. Carlsson, Lennart Sanzén and Ingemar Önsten

Dept. of Orthopaedics, Malmö University Hospital, S-205 02 Malmö, Sweden. Fax +46 40 336200

Between 1990 and 1996 we implanted 165 primary hydroxyapatite-coated Omnifit prostheses (Osteonics Inc) using the Dual Radius socket (PSL) and a 26 mm Co-Cr head. Thigh pain has been extremely rare even in the early postoperative course and only 1 stem has been exchanged.

After exclusion of cases with rheumatoid arthritis and congenital dysplasia there remained 136 hips in 129 patients. Micromotion and socket wear were evaluated by radiostereometry in 77 of these latter cases. An annual wear exceeding 0.2 mm was demonstrated in 24 cases. 13/136 sockets (10%) have been exchanged after on average 57 months due to loosening (9 cases) and/or polyethylene wear (9 cases) and/or osteolysis (10 cases).

Conclusion: The hydroxyapatite coated Dual Radius socket (PSL) has been shown to have an unpredictable wear pattern. The replaced hips may, in spite of an abnormally high wear and even presence of osteolysis, be painless which makes it imperative to follow patients with this type of implant regularly. The reason for the abnormal wear pattern is still obscure.

82. Abductor strength after total hip arthroplasty

Kjell Keisu¹, Maria Wiker², and Urban Lindgren¹

Departments of ¹Orthopaedics and ²Physical Therapy, Huddinge University Hospital, Stockholm, Sweden

Abductor strength is important for the functional outcome after hip arthroplasty. Decreased abductor strength can cause latent or overt abductor lurch and fatigue. Abductor strength is known to be related to several factors such as body height, sex, age and femoral head offset.

Material and methods: We measured the abductor strength of 33 hips (21 females, 12 males, mean age 66 years). In 15 cases we performed 3 measurements on three separate occasions within two weeks. The remainder were done at different time points after the operation. Concentric and eccentric measurements were done using a Kin-Com isokinetic dynamometer. We also measured isometric strength at -10, 0 and +10 degrees of abduction using the same equipment. All measurements were repeated twice on each occasion.

Results and Discussion: The measurements showed a high degree of reliability and the correlation between the isokinetic and the isometric measurements was excellent.

However, the isometric measurement was highly influenced by the degree of abduction and may be difficult to control for example if measurements are done by different examiners. The impact of femoral head offset was limited compared to other factors in this study.

Conclusion: Using the Kin-Com equipment reliable measurements of abductor strength can be done. Further studies are necessary to evaluate the correlation with gate parameters and outcome of surgery.

83. Fixation of hip-endoprotheses by bony ingrowth into a porous surface

Jens Decking¹, Anke Eckardt¹, Dieter Decking²

¹Orthopaedic Department, University Hospital Mainz, and ²Orthopaedic Department, St. Franziskus Hospital Münster, Germany

To allow for ingrowth of vital bone into a porous metal surface, an optimum pore-size and primary stability is mandatory.

Material: We report 6 year results of the anatomically shaped total hip replacement "tcl" (ESKA Medical, Lübeck). The proximal part of the stem as well as the metal-backed cup are covered by a porous CrCoMb surface 3mm deep. The tip of the stem is polished to reduce stress-shielding. The surface is a three-dimensional, open-pored metal-mesh structure with a pore-volume of 60% and a pore size of 1-2.5 mm.

Results: Ingrowth of vital bone was demonstrated by histological and electron-microscopic sections of explanted material. We examined 96 "tcl"-THR 6 years after implantation. There were no revisions during this period. There was one radiographic stem-loosening. Using the criteria of Engh (1987), there was bony ingrowth of the stem in 96%, fibrous ingrowth in 1.6%. We found stress-shielding in 9.4% despite the concept of proximal fixation by the porous coating.

Conclusion: Pore size and design of the examined metal-mesh-surface allows for sufficient bony ingrowth and seems a reasonable alternative in cementless fixation of THR.

84. Prosthetic migration during 2 years after cemented hip revision with impacted morselized allografts evaluated by RSA

Ewald Ornstein¹, Herbert Franzén², Ragnar Johnsson³, Per Sandquist¹, Anna Stefánsdóttir¹, Martin Sundberg¹

Departments of ¹Orthopedics, Hässleholm-Kristianstad Hospital, S-281 25 Hässleholm, ²Ängelholm County Hospital, S-262 81 Ängelholm, and ³Lund University Hospital S-221 85 Lund, Sweden

Aim: To evaluate by roentgen stereophotogrammetric analysis (RSA) the prosthetic fixation in cemented hip revisions with contained and impacted morselized allografts.

Material and methods: 18 femoral components and 21 acetabular revised for the first time due to mechanical loosening with the Exeter revision system were followed by RSA for 2 years. Indication for primary arthroplasty had been osteoarthritis.

Results: All 18 femoral components migrated in the distal direction (mean 2.5 mm), 6 in the medial (mean 1.3 mm), 2 in the lateral (0.5 and 1.0 mm) and 16 in the posterior (mean 2.9 mm). The migration rate decreased successively in all directions, and at 1.5 year the migration came to a standstill in all but 6 cases.

All but one of the 21 acetabular components migrated in the proximal direction (mean 2.2 mm), 6 in the medial (mean 0.8 mm), 6 in the lateral (mean 0.9 mm), 14 in the posterior (mean 1.0 mm) and 1 in the anterior (0.6 mm). The migration rate decreased successively in all directions, and at 1.5 year the migration came to a standstill in all but 7 cases.

There was no obvious association between migration rate and bone stock deficiency.

Conclusions: In cemented hip revisions with contained and impacted morselized allografts the prosthetic migration rate decreases successively, and in most cases the migration seems to come to a standstill within 1.5 years.

85. Postoperative biomechanical evaluation following CAD-based preoperative planning of revision total hip replacements

Philipp Lubinus

Lubinus Klinik Steenbekerweg 25 24106 Kiel, Germany

Preoperative planning (p.p.) for revision total hip replacements (THR) seems mandatory; especially with grossly migrated components it helps finding the correct lateralisation and height of the pivot point. P.p. also helps to choose implants with a CCD-angle and necklength to reestablish offset and leglength to avoid unwanted leglength-discrepancies and poor gait. Predicting the implants helps to avoid overreaming of weak bonestock; in some revisions CAD-based

p.p. helps to simulate various implants or to construct custom made ones.

Materials and methods: A retrospective geometric analysis of pre- and postoperative a.p.-x-rays was done on 100 consecutive revision THR's which were planned and operated by the author between June 1993 and March 1997. The study includes 79 complete revisions, 9 revisions of the stem only, 11 cup revisions and 1 case with a custom built femoral head.

Results: 1) we achieved a significant improvement of leglength-discrepancies: preoperative leglength averaged -14.5mm , postoperative the shortening was reduced to -3.0mm ; 2) the height of the pivot point was significantly normalized from in average $+12.1\text{mm}$ preoperatively to $+3.6\text{mm}$ postoperatively; 3) prediction of the exact stem was possible in 85% of the cases; 4) precise prediction of the cup was possible in 78%; and 5) the rate of postoperative luxations was 2%.

Conclusion: CAD-based p.p. is a helpful device to obtain a good accuracy of the postoperative geometric parameters in revision THR.

86. Postoperative biomechanical evaluation following CAD-based preoperative planning of total hip replacements—results of a prospective study

Philipp Lubinus

Lubinus Klinik Steenbekerweg 25, 24106 Kiel, Germany

Preoperative planning (p.p.) of a primary total hip replacement (THR) by drawing is helpful; it allows to foresee problems in finding the correct lateralisation and height of the pivot point, it helps to choose an implant with the right CCD-angle and necklength to establish the correct offset, thus helping to avoid unwanted leglength-discrepancies and poor gait.

Materials and methods: We developed in 1993 a CAD-based system for 2-dimensional preoperative biomechanical analysis and planning of primary total hip replacements. After evaluation of the precision of this tool we did a retrospective geometric analysis of pre- and postoperative a.p.-x-rays on 75 consecutive primary THR's (Group 1) which have been operated by the author between september 1993 and april 1995 using an anatomic shaped SP2-stem after a CAD-based p.p.. To reconstruct a healthy biomechanical situation we found it necessary to introduce an additional stem with a lowered CCD-angle in april 1995. Since then we evaluated our biomechanical goals prospectively in another 175 cases (Group 2).

Results: 1) with the additional implant we got closer to the goal of reconstructing the wanted biomechanical situation precisely; 2) prediction of the correct implants was possible for 98.4% of the cemented stems, 96% of the cemented cups and more than 92.6% of the uncemented ones; 3) the intended use of a ceramic head was possible in 97.6%; 4) clinical relevant ectopic bone formation was below 2%; and 5) the

Table. Average (mm), s, maximum

	preoperative	postoperative		p-value
Leglength-discrepancy				
average		-14.5	-3.0	0.001
s		± 14.5	± 9.4	
maximum		-67.0	-30.0	
Offset (muscle-leverarm)				
average		+0.3	+0.6	n.s.
s		± 11.0	± 11.6	
Pivot point lateralisation				
average		-1.8	-1.8	n.s.
s		± 9.9	± 8.7	
Pivot point height				
average		+12.1	+3.6	0.001
s		± 10.5	± 8.8	
maximum		+52.0	+26.0	

Table. Average (mm), s

	Group 1	Group 2	p-value
Postoperative leglength-discrepancy average s	+4.1 ±6.7	+3.1 ±6.0	n.s.
Offset (muscle-leverarm) average s	-5.7 ±6.2	-1.2 ±6.0	0.05
Pivot point lateralisation average s	+0.1 ±5.4	-1.7 ±5.6	n.s.
Pivot point height average s	-0.2 ±5.5	+1.6 ±5.1	n.s.

rate of postoperative luxations was below 1%.

Conclusion: CAD-based p.p. is a helpful device to obtain a good accuracy of the postoperative geometric parameters in primary THR. This improved accuracy seems to coincide with a better early functional result and maybe a better long-term result.

Session 23: Free papers

87. Arthroscopic resection of subcutaneous bursitis over patella and olecranon

Poul Verner Madsen, Kaj Døssing and Gert Kristensen

Dept. of Orthopaedic Surgery, Aalborg Hospital, Denmark

The technique of arthroscopic bursectomy is described. Results are evaluated compared to "open" surgery.

Patients and methods: Data were registered from case records of all patients operated on with the diagnosis of bursitis in the period 1/1/1994 – 30/6/97. A bursitis was considered infected in cases with a positive culture from a preoperative aspirate or a peroperative sample, or when bacteria were present at microscopy of aspirates. Patients were interviewed by telephone at follow up.

Results: Ten female and 60 male patients were found to have the index diagnosis and operation. Nineteen patients had been operated arthroscopically (AR), 19 excised and primarily sutured (EPS), and 32 incised (I).

Operative technique	AR	EPS	I
No. infected/total	14/19	5/19	26/32
Median operation time, min	31	30	18
Median hospitalization, days	2	2	4,5
Patients reoperated	0	0	22
Patients readmitted	0	1	6
Healed after 2 wks/followed up	14/16	6/18	3/27
Healed after 4 wks/followed up	16/16	14/18	14/27

16 patients in the I group had one reoperation (12 of these were secondary closures), 3 had 2 reoperations, one had 3, one 4, and one patient had 7 reoperations. At interviews greater patient satisfaction was found among AR patients.

Conclusion: Arthroscopic resection is a safe and effective operation with short hospitalization time.

88. Torsional strength reduction by cortical defects in human femora

PDS Dijkstra¹, M ten Have², CJ Snijders³, T Wiggers⁴

Department of ¹Orthopedic Surgery, Westeinde hospital, Den Haag, ²Laboratory for Engineering Mechanics, University of Technology, Delft, ³Biomedical Physics and Technology, Erasmus University, Rotterdam, and ⁴Surgical Oncology, Daniel den Hoed Cancer Center, Rotterdam⁴, The Netherlands

Analyses of torsional strength reduction on large longitudinal transcortical defects were made in an in vitro experiment. Fifteen fresh frozen femur pairs were collected from human cadavers. At random, in one femur an oblong hole was drilled in the cortex of the subtrochanteric region, the other served as control. The defect length (d) differed to bone diameter (D) in ratio 0.5 to 2. The width was one-quarter of the bone diameter. At each femur a torsional load with

a low velocity angle was obtained to failure. Strain gauge measurements were performed. Bone mineral density (BMD) of the cortex was estimated by quantitative computed tomography scan measurements.

Except three for femora, a spiral fracture occurred in the lesion. In the control group this was usually at the distal site of the bone. In a transcortical defect with a defect length once the bone diameter a small strength reduction was measured. In case of defect length twice the bone diameter a 50% strength reduction was estimated. The location of maximum local stress points were strongly influenced by the defect length, depending on the helix angle at the initial fracture site. The helix angle changed from median 45° in the smallest defects, to median 34° in the largest defects. The corrected strain gauge value showed a significant correlation between the defect length and the increasing strain reduction. The relation torque at failure in relation to BMD was significant for the proximal region of the control group. Influences of the site of the cortical defect and geometry of the femur were studied in another experiment of seven shortened paired femora, left after the first experiment. A significant rank-correlation between ratio d/D and strength reduction was estimated. The 50% torsional strength reduction shifted to ratio d/D 1.

In conclusion, a progressive torsional strength reduction occurred when a transcortical defect at the subtrochanteric region of the femur with a ratio defect length to the bone diameter exceeds one.

89. Extramedullary fixation implants for trochanteric femoral fractures—a meta-analysis of randomised trials

Martyn J Parker, William J Gillespie, Helen H Handoll

Orthopaedic Department, Peterborough District Hospital, Thorpe Road, Peterborough PE3 6DA. England.

Methods: All randomised controlled trials comparing different surgical treatment methods for extracapsular hip fractures were identified using pre-defined search criteria of the Cochrane collaboration. All trials were independency assessed for methodology and data extracted from each study.

Results: 34 randomised trial were identified, involving over 7,000 patients and 10 different implants. Information could only be used from 26 studies as the remaining trials were ongoing or inadequately reported. Summation of results indicated that fixed nail plates (3 studies), Ender nails (7 studies), Harris nail (1 study), Küntscher nail (1 study) and the Gamma nail (10 studies) had a higher risk of complications and revision surgery in comparison to the sliding hip screw. For the Medoff plate, Pugh nail, hemiarthroplasty and the Intramedullary hip screw, there was only one completed study on each implant which was insufficient to make definite conclusions.

Conclusions: Summation of individual randomised trails in a comprehensive meta-analysis provides the foremost medical evidence for determining the optimum method of treatment.

90. Effect of nasal salmon calcitonin on post-traumatic osteopenia following ankle fracture

Michael M Petersen¹, Jes B Lauritzen¹, Peter Schwarz², and Bjarne Lund¹

Depts. of ¹Orthopedics, Rigshospitalet, and ²Clinical Biochemistry2, Hvidovre Hospital, Denmark

We investigated the preventive effect of salmon calcitonin (sCT) on postfracture osteopenia following ankle fractures.

Material and methods: 24 patients with ankle fracture treated by open reduction and internal fixation were randomized to placebo or 200 IU nasal sCT for 3 months in a prospective, double-blind design. 3 patients were excluded leaving 11 patients in the placebo group and 10 in the sCT group for the study. Bilateral measurements of bone mineral content (BMC) in the coronal plane of the proximal tibia were performed by dual photon absorptiometry within 7 days after the fracture and after 1.5, 3, and 6 months.

Results: 3 months after the fracture BMC in the injured legs decreased by 12.5% (p=0.01) in the placebo group, and 5.3% (p=0.14) in the sCT group. In the healthy legs BMC decreased by 1.5% (p=0.14) in the placebo group, while BMC in the sCT group increased by 5.3% (p=0.20). When evaluating the effect of sCT on changes in BMC following ankle fractures, no statistically significant (p=0.25) effect was observed in the injured legs, but in the healthy legs a significant (p=0.02) difference between the sCT and placebo group regarding the changes in BMC from baseline to 3 months postoperatively was seen.

Discussion: Nasal sCT may to some extent, but in this study not significantly, reduce postfracture osteopenia, in addition to a significant increase in BMC in the healthy leg.

91. Tranexamic acid reduces local fibrinolysis, blood loss and blood transfusions in knee arthroplasty

Göran Benoni, Stefan Lethagen, Hans Fredin

Depts. of Orthopaedics and Coagulation Disorders, Malmö University Hospital, Sweden.

Blood loss in knee arthroplasty is sometimes abundant and blood transfusions are frequently prescribed.

The tourniquet used in these operations induces local fibrinolysis and augments the general stimulation of the fibrinolytic system caused by the surgical trauma.

Patients and methods: We made a randomised, double-blind study of 86 patients, operated on with total knee arthroplasty. A dose of 10 mg/kg body-weight of tranexamic acid or placebo was given shortly before the release of the tourniquet and repeated three hours later. Blood samples for analysis of fibrinolysis were taken from the wound and peripheral blood during and after the operation.

Results: The mean blood loss was 730 ± 280 ml in the tranexamic acid group as against 1410 ± 480 ml in the placebo group (p<0.001). The number of patients receiving

blood transfusion as well as the number of blood units transfused were reduced to one-third in the treated group. The concentration of D-dimers in blood from the wounds was significantly lower in the treated group.

The number of thromboembolic complications was the same in both groups.

Conclusion: Tranexamic acid, effectively reduces blood loss and blood transfusions in knee arthroplasty, mainly by reducing the local fibrinolysis in the wound.

92. Inhibition of enzymatic activity in osteoarthritic cartilage—a future treatment?

L Dahlberg^{1,4}, C Billingham¹, M Ionescu¹, A Reiner¹, Ml Tanzer², D Zukor³, J Chen³, H van Wart³, A Robin Poole¹

¹Joint Diseases Laboratory, Shriners Hospital for Children, McGill University, Montreal, CANADA, ²Division of Orthopaedics, McGill University, ³Roche Bioscience, Palo Alto, CA, and ⁴Dept. of Orthop. UMAS, Malmö, Sweden

Type II collagen forms the fibrillar network that provides the articular cartilage with its tensile properties. This molecule, excessively degraded in osteoarthritis (OA), is cleaved in a single site by collagenases.

Methods: Femoral knee articular cartilage, obtained at joint replacement in eleven OA patients, or at autopsy in five non-arthritic patients, were cut into pieces, mixed, weighed and placed in culture wells for 14 days. Triplicate cultures were treated with Roche MMP inhibitors: either a preferential collagenase 13 inhibitor, or a broader spectrum collagenase inhibitor. Media were examined by immunoassay for the carboxyterminal neopeptide produced by cleavage of the type II collagen by collagenase. Proteoglycan release into the culture media was analyzed as glycosaminoglycan (GAG) by the DMMB assay.

Results: Analysis of normal versus OA cartilages revealed a significant increase in total release of the collagenase-generated neopeptide in the OA group. Release of the collagenase-generated neopeptide from cartilages treated with a preferential collagenase 13 inhibitor, showed significant inhibition of neopeptide release in OA group as well as in non-arthritic cartilages. The broader spectrum inhibitor, produced significant inhibition of collagen cleavage only in the OA group. The release of GAG was not different in OA compared to non-arthritic cartilages. These inhibitors did not inhibit the release of GAG.

Conclusions: This study provides evidence for increased cleavage of type II collagen by collagenase in cultured OA cartilages which was not accompanied by increased proteoglycan degradation.

The inhibition of release of the collagenase-generated neopeptide in OA and non-arthritic articular cartilages, indicate a role for collagenase(s) in the physiology and pathophysiology (OA) of articular cartilage.

Inhibition of collagenases may prove of value in the treatment of cartilage degeneration in OA.

93. Early cartilage degeneration in the knee can be detected non-invasively by gadolinium-MRI

Carl Johan Tiderius¹, Lars E Olsson², Peter Leander³, Rickard Claesson¹, Olof Johnell¹ and Leif Dahlberg¹

Depts. of ¹Orthopedics, ²Radiation Physics, and ³Radiology, University Hospital, Malmö, Sweden.

In order to detect early pathology in osteoarthritis, new non-invasive methods need to be developed. Gadolinium (Gd-DTPA²⁻) is a charged paramagnetic contrast compound. Previous in vitro experiments have shown a relationship between Gd-DTPA²⁻-uptake and cartilage proteoglycan content. The purpose of this study was to examine if

Gd-DTPA²⁻ MRI can be used to identify cartilage pathology in vivo.

Methods: Four patients with knee pain, normal radiography and arthroscopically verified cartilage fibrillations in the medial femoral compartment but normal cartilage in the lateral compartment, and one healthy volunteer were included. MRI was performed before and sequentially after intravenous injection of Gd-DTPA²⁻ (Magnevist, 0.6 ml/kg). We calculated the percentage difference between the medial and lateral compartments with regard to both maximum Gd-DTPA²⁻ uptake and uptake velocity.

Results: The median time for maximum uptake was 70 minutes. All patients had higher Gd-DTPA²⁻ uptake in the fibrillated medial femoral cartilage as compared to the lateral side. The mean percentage difference was 70% (s.d. (40%). Likewise, the uptake velocity was higher medially than laterally (mean percentage difference 80%, s.d. (40%). The healthy volunteer showed similar uptake in the medial and lateral compartments and the same uptake velocity in both compartments.

Conclusion: Our study demonstrates that cartilage changes, consistent with early OA, can be non-invasively visualized by Gd-DTPA²⁻ enhanced MRI. This new approach may facilitate the identification of patients with cartilage pathology in the knee and the intervention of new drugs in clinical trials.

94. Changes in the stiffness of the human tibial cartilage-bone complex in early-stage osteoarthritis

Ming Ding, Michel Dalstra, Frank Linde, Ivan Hvid

Orthopaedic Research Laboratory, Aarhus University Hospital (ÅKH), 8000, Aarhus C, Denmark

Previous investigation has shown that cartilage and subchondral trabecular bone function as a mechanical unit.¹ This study aimed to examine the stiffness association and unit function of the cartilage-bone complex in early-stage osteoarthritis (OA) compared with normal age-matched groups.

Material and methods: Cylindrical human tibial cartilage-bone complex specimens were removed from nine early-

stage medial OA tibiae (mean age=74 years) and ten normal age-matched tibiae (mean age=73 years). These specimens were divided into four groups: OA, lateral comparison, medial age-matched, and lateral age-matched and were tested to 0.5% bone strain with a novel technique to obtain the stiffnesses of both cartilage and bone simultaneously.

Results and Discussion: A pronounced reduction in the stiffnesses of both OA cartilage and subchondral bone was found, when compared with the medial age-matched group. OA cartilage was significantly thinner than that of the lateral comparison and the medial age-matched control groups. The stiffnesses did not correlate between OA cartilage and bone, whereas the stiffness relationships between cartilage and bone remained significant for the three control groups. The present study suggests that both cartilage and bone in early-stage OA are mechanically inferior to normal, and that OA cartilage and bone have lost their unit function to mechanical loading.

Reference: (1) Ding M, Dalstra M, Linde F, Hvid I. *Clinical Biomechanics* 1998; Accepted.

Session 24: Hip revision

95. Femoral component migration after revision of a total hip arthroplasty with impaction bone grafting

Jouko Pekkarinen, Antti Alho, Jyri Lepistö, Pekka Ylinen, Mauno Ylikoski, Kaj Tallroth, Timo Paavilainen

ORTON Orthopaedic Hospital, Invalid Foundation, Helsinki, Finland

During 1993–1995, 68 impaction bone grafting revisions were performed at ORTON Orthopaedic Hospital, Invalid Foundation, Helsinki. In this study we aimed at evaluating radiographical femoral stem subsidence. In 36 cases Exeter X-Change technique (cemented) and in 32 cases Bi-Metric Allografting technique (uncemented) was used. Most bone defects were grade III or IV in Endo-Klinik classification. The median age of the patients was 71 (40–78) years. In 15 cases an additional fixation was needed because of bone defects, cracks or fractures. We used mean 1.9 (1–5) allograft femoral heads for impaction grafting. Mayo hip score rose significantly postoperatively indicating improved clinical result during the follow-up period of 16 (12–39) months. In 4 cases new revision was performed. There were 7 late post-operative fractures which were reoperated. All these fractures united. During the follow-up period the mean subsidence was 3 (0–20) mm.

In conclusion, our preliminary results are satisfactory. However, in difficult revision cases with large femoral bone defects, the techniques include a high risk of intra- and post-operative fractures, which may be prevented by precise pre-operative selection of the patients. In case of osteolysis near the tip of the prosthesis, a longer stem ought to be used. Significant (over 10 mm) early stem migration may indicate rotational instability especially in uncemented impaction bone grafting.

96. Results of cemented revision hip arthroplasty

Peter Hultmark, Johan Krrholm, Christer Strmberg, Henrik Malchau, Peter Herberts.

Dept. of Orthopaedics, Sahlgrenska University Hospital, S-413 45 Göteborg, Sweden

This study evaluated revisions using second and third generation cementing technique.

Patients and methods: 125 hips in a consecutive study of cemented revisions were operated during 1982 to 1989. Hips revised more than one time and infections were excluded. Repeated clinical and radiographic evaluations were done prospectively for a minimum of 7 years. There were 70 revised cups and 109 stems. The reason for revision was aseptic loosening in 120 hips, 2 dislocation, 2 implant fracture and one cartilage wear. The mean age at the revision was 70

years (28–88) and average radiographic follow-up was 8 years (3–13). Bone defects were classified according to Gustilo and Pasternak and the Endo-Klinik, osteolyses according to Goetz. Cox regression analysis was used.

Results: 5 cups were rerevised and further 12 were radiographic failures corresponding to 10-year survival rates of 93±7% (end-point: rerevision) and 77±11% (end-point: rerevision or loosening=total failure), respectively. As regards the later type of failure the Charnley cup performed better ($p=0.0008$) than the other designs (mainly metal-backed Spectron and polyethylene Christiansen cups). The width of the cement mantle in zon 4 implied increased risk of total cup failure ($p=0.0003$) and younger age at revision ($p=0.001$). 7 stems were rerevised and further 5 were radiographically loose (10 year survival revision: 92±6%; total failure: 87±8%). Endo-Klinik grade III ($p=0.04$), postoperative radiolucency region 4 ($p=0.04$) and 6 ($p=0.002$), use of short stem ($p=0.008$) and younger age ($p=0.0001$) implied increased risk of total stem failure. The hip and pain scores at the latest follow up were 73±16 resp. 40±9.

Conclusion: Correct implant selection and optimum cementing technique are important steps to improve the results of cemented hip-revision.

97. Evaluation of a new impaction technique and graft preparation in a revision total hip arthroplasty

J Höstner, J Kärrholm, H Malchau

Dept. of Orthopaedic Surgery, Sahlgrenska University Hospital, Göteborg, Sweden

We have developed a laboratory model corresponding to revision of the femoral component using impacted allograft (1). In this study a new surgical technique to obtain impaction of the graft and the influence of marrow fat in the graft was studied.

Material and methods: 22 femoral stems (Spectron EF) were cemented into femoral specimens of adult sows. Before cementation bone chips were impacted into the distal half of the canal using cylindrical impactors with increasing diameter (conventional technique, $n=10$, Group 1). In 12 cases impaction was obtained by using rotating metallic cones of increasing size. In 6 of these cases (Group 2) and in Group 1 fat was removed from the graft using water tempered at 37°. In the remaining 6 specimens the graft was used without any further treatment (Group 3). The specimens were cyclically loaded in an MTS machine (250–3250 N, 5 Hz, 4 hours = 72,000 cycles). The micromotions of the implants was measured with radiostereometry.

Statistics: Mann Whitney test.

Results: The use of impaction technique did not influence the recorded micromotions. Increased subsidence was recorded when no fat had been removed from the allograft (Group 2 vs. 3: preload 200N: $p=0.009$; 1200N: $p=0.04$). The inducible subsidence after loading was also bigger ($p=0.04$).

Discussion: The new impaction-technique with rotating phantoms had the same stability as the standard procedure. It is our hope that it also will reduce the risk of peroperative fractures in clinical practice. Defatted allograft resulted in smaller micromotions, probably because of higher internal friction.

References: 1. Höstner J, Kärrholm J, Malchau H: 43rd Annual Meeting, Orthopaedic Research Society 1997: 829.

98. Biochemical, microbiological and biomechanical analysis of allogenic bone transplant treated with thermal disinfection process at +80°C

Alfredo Lispi, Claudio Nati, Franco Laurenza

Azienda Ospedaliera S. Giovanni-Addolorata, Italy

The continuous evolution of techniques in the orthopaedic surgery, has increase the need of biologic bone transplants. Femoral heads collected during a hip prosthesis, disinfected at +80°C and preserved at -80°C seems to be the most efficient method.

In our Department, we use a disinfection device called Lobator, according to Marburg University method. We made biochemical, microbiological, biomechanical and histologic analysis of bones treated in this way and stored at -80°C for 30 days and compared them with untreated ones.

The aerobic and anaerobic blood culture proved the sterile condition. Intercellular reticular stroma of bone marrow disappeared, nevertheless this has no biomechanical relevance. The cellular structure has no important difference; the osteocytes show picnotic nucleus. The trabecula protein matrix looks quantitatively reduced without evident modification of structure. The loss of biomechanical stability is only between 10% and 20%. These results are much better than any other disinfection method like, gamma irradiation, autoclave, chemicals or methods of deproteinizations or freeze-dryer or lyophilised.

With our biochemical, microbiological and biomechanical analysis, we demonstrated that the thermal disinfection at +80°C of allogenic bone transplants is a method for sure biological transplants, safe from the risk of pathogenic transmission.

99. Management of a central Bone Bank with femoral heads using a thermal disinfection method

Francesco Falez, Fabio Mariottini, Lamberto Perugia

I Clinica Ortopedica e Traumatologica Università degli Studi di Roma "La Sapienza" Roma, Italy

Bone deficit conditions can be solved by homologue bone tissue graft managed by bone banks. The author presents the criteria and rationality of the management of a central bone

bank with femoral heads, using the method of thermal disinfection at +80°C in Ringer lactate solution to eliminate the risk of cross contamination and HIV transmission.

Material and methods: The University of Rome developed the Bone Bank organised with peripheral centres providing the central bank with femoral-heads removed during hip prosthesis operations, according to a structured protocol. Heads which can be returned treated to those centres in case of need.

The femoral-heads are treated with Lobator disinfection device (that inactivates major pathogenic bacteria and viruses, likewise syphilis and HIV) and then stored at -80°C.

Results: This management permits: an increase of bone availability; immediate availability of the bone since no need of the second HIV test; drastic reduction of secondary bone contamination and thus of discarded femoral heads; reduction of cost; easier handling of the bank.

Conclusion: The Centralised Bone Bank established at the University of Roma obtains a great quantity of bone tissue at low operational cost and increases the safety of these surgical allografts using the described thermal disinfection system.

Session 25: Sports and foot

100. Semitendinosus tendon regeneration after harvesting for ACL reconstruction

Karl Eriksson, Torsten Wredmark, Hans Larsson, Per Hamberg

Depts. of Orthopedics and Radiology Södersjukhuset, Stockholm and Orthopedics Huddinge hospital, Huddinge, Sweden

Utilizing the semitendinosus and gracilis tendons in reconstruction of the ACL has become more common during the last years. In 1992, Cross published findings indicating a regeneration potential in the harvested tendons. There were only four patients out of 225 thoroughly examined, therefore we decided that the aim of this study was to examine a number of consecutive patients where the semitendinosus tendon was harvested for ACL reconstruction.

Material and methods: 11 consecutive patients who underwent ACL reconstruction with Semitendinosus graft were examined 6-12 months postoperatively with MRI. Another two patients were examined within two weeks after surgery. The median age of the patients was 24 years and there were eight males and three females. The right knee was involved in six patients and the left knee in five.

An open low field 0.2T Siemens Open MRI was used for examinations T1 and T2 weighted transaxial sequences over the Thigh and the Knee joint and in some instances additional sagittal sequences were performed. ROI analysis of the pixel value of the signal and area determinations on transaxial sequences both on the involved and the healthy side were performed.

Results: In 8 of the 11 patients examined 6-12 months postoperatively a regenerate of the semitendinosus tendon with a normal anatomical insertion in pes anserinus was found. In some patients the regenerate was thicker than normal with a higher signal on T1 weighted sequences. In two patients all acquired data along the regenerated tendon were the same as on the healthy side. In three patients the regenerated tendon fused into the semimembranosus tendon proximal to the knee joint. When the examination was performed two weeks after surgery no tendon or scar structure was identified in the harvest location.

In midhigh level the semitendinosus muscle had a smaller area and a higher signal than on the normal side.

Conclusion: This examination confirms the previous findings reported by Cross. Our results indicated that the regeneration capacity of the semitendinosus tendon is considerable, both in anatomical and structural parameters, at least when harvested with the technique in this study. The muscle function e.g. fiber composition, EMG and torque has to be further analysed and correlated to the present findings.

101. Fixation of the proximal osteotomy of 1st metatarsal bone and TMT-I-arthrodesis with self-reinforced absorbable polylactide screws for the treatment of hallux valgus and metatarsus primus varus—preliminary results of the use of SR-PDLLA-screws

A Joukainen, E K Partio, P Helevirta, P Törmälä, P Rokkanen

Iisalmi District Hospital, Iisalmi, Biomaterials Laboratory, Tampere University of Technology, Dept. Orthop. and Traum., Helsinki University Central Hospital, Finland

SR-PLLA (self-reinforced poly-L-lactide) screws has been in Finland in routine use in clinical practise near ten years. We like to report early results of the use of SR-PLLA and SR-PDLLA-screws (strength retention 36 and 12 weeks respectively) in hallux valgus surgery.

Patients and methods: 13 patients and 14 feet with hallux valgus and metatarsus primus varus were treated in Iisalmi District Hospital in 1997. Four patients with concomitant instability of first TMT-joint were treated with arthrodesis and ten with proximal osteotomy of 1st metatarsal bone. All patients were women. The patients were randomly allocated in respect of screws used in the operation. The follow-up time was 12 weeks. Proximal wedge osteotomy about 1.5 cm from TMT-joint was fixed transiently with clamps and then with either SR-PLLA or SR-PDLLA screw, 4.5 mm in outer diameter and 35–50 in length. In arthrodesis we removed articular surface of the joint and bone to achieve an anatomic intermetatarsal angle. The fixation was same as in osteotomy. In half of osteotomies and arthrodeses were used SR-PDLLA screws and those fixations were compared with SR-PLLA-screw fixations. The mean age of patients was 53 (31–70) years.

Results: All osteotomies and arthrodeses united. The mean operation time was 40 (10–52) min. At 12 weeks the movement of MTP joint was 55 (30–85) on average. The correction of MTP-angle was 12.7 (3–22) degrees after osteotomy and 19 (13–29) after arthrodeses. The correction of intermetatarsal angle in osteotomized patients was 8.8 (2–13) degrees and after arthrodesis 7 (1–13). The mean shortening of 1st metatarsal bone was 1.0 (-3 to +5) mm after osteotomy 1.3 (-1 to +3) mm after arthrodesis analyzed in the direction of 2nd metatarsal bone. In respect of screw used in this series there was no difference in union rate, and there were no failures of fixation. The correction of intermetatarsal angle after SR-PDLLA-screw fixation 8.6 (2–13) degrees and after SR-PLLA-screw fixation 8.0 (2–13) degrees.

Conclusion: The proximal wedge osteotomy of 1st metatarsal bone and 1st TMT-arthrodesis can be safely fixed with absorbable SR-PDLLA and SR-PLLA screws without subcutaneous irritation because of thin subcutaneous tissue.

102. Proximal or distal osteotomy for hallux valgus fixed with absorbable implants

Esa K Partio, Esko Partio¹, Eero Hirvensalo, Antti Joukainen², Pentti Rokkanen

Dept. of Orthop. and Traum., Helsinki University Central Hospital, ¹Jämsä District Hospital, ²Iisalmi District Hospital, Finland

It is possible to correct metatarsus primus varus by using proximal or distal osteotomy of 1st metatarsal bone fixed with self-reinforced absorbable implants.

Material and methods: In this randomized study has been treated 47 patients. Altogether there was 30 distal Chevron osteotomies and 34 proximal osteotomies. The mean age was 41.3 (16–59) in distal osteotomies corresponding 39.2 (20–58) years in proximal. The follow-up time was 3 years. Statistically there was no differences between the groups in respect of preoperative status. There was 2 male in proximal osteotomies and one in distal. In distal osteotomies after union excision has been performed distal V-shape osteotomy, distal part lateralized and fixed with self-reinforced absorbable rod 2.0 mm in diameter. In proximal osteotomies were three-angular part removed proximally of the first metatarsal bone, transient fixation was performed with clamps and then fixed with self-reinforced absorbable screw 4.5 mm in outer diameter. In the proximal osteotomies we used 6 weeks tarsal plaster cast immobilization and in distal osteotomies bandage and all patients allowed use partial weight bearing on lateral side.

Results: In proximal osteotomies were noticed 3 delayed union (more than 6 weeks) and 3 slight redisplacement. In distal osteotomies there was one delayed union and 2 redisplacement. The difference was not statistically significant. It was not possible to find in this series the intermetatarsal angle, in which it is better to use proximal or distal osteotomy. In proximal osteotomies the correction of intermetatarsal angle ($p < 0.01$) and the correction of MTP-angle ($p < 0.01$) were better than in distal osteotomies. The shortening of 1st metatarsal bone was less in distal osteotomies ($p < 0.05$), but compared with the 2nd metatarsal the difference was not statistically significant. In respect of cosmetic and subjective results the proximal osteotomy gave the better result ($p < 0.05$).

Conclusion: In this series the proximal osteotomy seems to be better for the treatment of hallux valgus and metatarsus primus varus. Absorbable fixation seems to be sufficient both in distal and proximal osteotomy of the first metatarsal bone.

103. Bioabsorbable polyglycolide (SR-PGA) and polylactide (SR-PLLA) rods in treating osteochondritis dissecans of the knee

Pertti Tuompo, Vesa Arvela, Esa K Partio, Pentti Rokkanen
Helsinki University Central Hospital, Dept. of Orthopedics, Helsinki, Finland

Treatment of osteochondritis dissecans is still controversial. Different methods of biologic fixation have been studied. The present study will describe 24 patients with osteochondritis dissecans of the knee fixed with bioabsorbable self-reinforced polyglycolic acid (SR-PGA) and polylactic acid (SR-PLLA) rods.

Patients and methods: There were 23 medial condyle osteochondritis dissecans and one in the lateral condyle. The average age of the patients was 25 years (16–48). The follow-up time was 3.3 years (1–7.6). There were six intact lesions, three early separated, eleven partially detached and four loose bodies. SR-PGA rods were used in 12 patients and in 11 patients SR-PLLA rods were used and in one patient both SR-PGA and SR-PLLA rods. The diameter of the rods was 1.1–2 mm. In each case the rod was inserted subchondrally and in nine cases arthroscopically using a special instrument.

Results: The clinical result was excellent in 13 patients, good in 6 patients, fair in one patient and poor in 4 patients. In the radiological evaluation, the fragment healed in 19 cases. There was one synovitis with SR-PGA fixed patient (1/13).

Conclusion: We conclude that SR-PGA and SR-PLLA can be used intra-articularly in the fixation of osteochondritis dissecans with favourable results.

104. Active physical training is an effective treatment of adductor related groin pain in athletes—results of a randomised clinical trial of two interventions

Per Holmich^{1,5}, Pernille Uhrskou², Lisbeth Ulnits², Inge-Lis Kanstrup³, Milchael Bachmann Nielsen⁴, Kim Krosgaard⁵

¹Clinic of Sportsmedicine, Dept. of Orthopaedic Surgery, Amager Hospital, ²Dept. of Rheumatology, Herlev Hospital, ³Dept. of Clinical Physiology, Herlev Hospital, ⁴Dept. of Radiology, Glostrup Hospital, ⁵Copenhagen Trial Unit, Institute of Preventive Medicine, H:S Kommunehospitalet. All from Copenhagen, Denmark.

Groin pain in athletes is often a longstanding problem. No treatments have been documented scientifically. Adductor related pain characterized by i) palpatory pain at the insertion of the adductors to the pubic bone, ii) pain at adduction against resistance and iii) pain during and after sprinting, sudden side movements and kicking, is one of the most frequent diagnoses. Objective: To compare the efficacy of two intervention strategies directed towards adductor related groin pain in consecutive athletes.

Material and methods: 68 male athletes with adductor related groin pain were randomised to either treatment A: strength training of the adductor and abdominal muscles combined with coordination- and balance training or to treatment B: transcutane nerve stimulation, laser treatment, stretching and transverse friction massage. Both groups were treated for 8–12 weeks. Hereafter both groups were

given verbal as well as written instruction aiming at further rehabilitation towards sport.

The patients were evaluated at 4 weeks and 4 months after treatment withdrawal by a masked observer regarding both subjective as well as clinical symptoms.

Results: Median age was 30 (20–50) years. Most patients were soccer players (n = 54). The average duration of symptoms was 67 weeks. 59 patients completed the treatment programmes, 29 in treatment A and 30 in treatment B. At the time of randomisation the two groups did not differ significantly. At the evaluation 4 months after treatment withdrawal 79% of the patients in group A and 13% in group B had returned to their previous level of sport with no pain neither subjectively nor objectively. This difference is statistically significant (p < 0.0001).

Conclusion: Treatment of athletes with longstanding groin pain with an active program of specific exercises was significantly better than conventional physiotherapy. With the active training programme 79% returned to sport at the same or even a higher level without any groin pain.

105. Intraarticular glucocorticoid, morphine and bupivacaine reduce pain and convalescence after arthroscopic treatment of impingement of the ankle joint

Sten Rasmussen¹ and Henrik Kehlet²

Depts. of ¹Orthopaedic Surgery* and ²Surgical Gastroenterology, Hvidovre University Hospital, Denmark.

Convalescence after treatment of impingement of the ankle joint by arthroscopic removal of bony spurs and synovitis is dependent on pain and the inflammatory response. The aim of the study was therefore to investigate the effect of intra-articular bupivacaine + morphine + methylprednisolone versus saline on post-arthroscopic pain, mobilisation and convalescence.

Material and methods: In a double-blind randomised study 36 patients undergoing arthroscopic treatment of impingement of the ankle joint were allocated to intraarticular saline or bupivacaine 15 mg + morphine 5 mg + intraarticular methylprednisolone 40 mg. Pain during walking, use of crutches and duration of sick leave were assessed.

Results: Combined methylprednisolone, bupivacaine and morphine reduced pain, time of immobilisation and duration of convalescence after arthroscopic removal of bony spurs and synovitis of the ankle joint.

Conclusion: A multimodal analgesic and antiinflammatory treatment may enhance postarthroscopic convalescence, which depends on the trauma induced inflammatory response and pain.

106. Intraarticular glucocorticoid, morphine and bupivacaine reduces pain, inflammatory response and convalescence after arthroscopic meniscectomy

Sten Rasmussen¹, Allan S Larsen¹, Søren T Thomsen¹, Henrik Kehlet²

Depts. of ¹Orthopaedic Surgery, Hjørring Hospital and ²Surgical Gastroenterology, Hvidovre University Hospital, Denmark

Convalescence after arthroscopic meniscectomy is dependent on pain and the inflammatory response. The aim of the study was therefore to investigate the effect of intraarticular bupivacaine + morphine + methylprednisolone versus bupivacaine + morphine or saline on post-meniscectomy pain, mobilisation and convalescence.

Material and methods: In a double-blind randomised study 60 patients undergoing arthroscopic meniscectomy were allocated to intraarticular saline, intraarticular bupivacaine 150 mg + morphine 4 mg or the same dose of bupivacaine + morphine + intraarticular methylprednisolone 40 mg. Pain during movement and walking, leg muscle force and joint effusion, use of crutches and duration of sick leave were assessed. The acute phase proteins CRP and orosomucoid were assessed.

Results: Combined bupivacaine and morphine reduced pain, time of immobilisation and duration of convalescence. Addition of methylprednisolone further reduced pain, joint swelling and convalescence, improved muscle function and prevented the inflammatory response (acute phase protein).

Conclusion: A multimodal analgesic and antiinflammatory treatment may enhance postarthroscopic convalescence, which depends on the trauma induced inflammatory response and pain.

Poster session

P1. The Cochrane database and orthopaedics

Martyn J Parker, William J Gillespie, Helen H Handoll

Orthopaedic Department, Peterborough District Hospital, Thorpe Road, Peterborough PE3 6DA. England

The Cochrane collaboration is an international network of health care workers who are interested in developing and maintaining comprehensive, regularly updated critical reviews of evidence from randomised controlled trials. Each review is added to the Cochrane database of systematic reviews which is published quarterly on CD ROM and distributed on an international basis. New studies can be added to the review and individuals can add comments and correspond with the review authors.

The musculoskeletal injuries review group aims to review studies on the prevention, management and rehabilitation of fractures, dislocations and soft tissue injuries. Reviews completed to date by the Musculoskeletal Injuries group are mainly related to hip fractures and include prevention of falls, traction, thromboembolic prophylaxis, choice of implants and rehabilitation. Other reviews in progress relate to wrist, ankle and back injuries. All completed reviews may be readily accessed by referring to the Cochrane database.

Once completed the database will assist the orthopaedic surgeon defining the optimum method of treatment based on the best available medical evidence.

P2. Computer simulation of external fixators stiffness

A V Karlov¹, V N Likhachov² and B A Luckshin²

¹Centre of Orthopaedics and Medical Material Sciences of SB of RAMS and ²Clinical Scientific Production Association "Biotechnika", Tomsk, Russia

A purpose of this work is determination of factors purposeful changing stiffness of as-telescopic external fixators (ATEF) to optimise healing. For this the computer model for calculation of ATEF stiffness taking into account all factors: wires, rods, segments, anchoring conditions, material property and fixators configuration was developed.

Method: ATEF elements were represented as following. Wire is "tensioned thread" or elastic beam. Support is beam with variable section. Load is applied to point of wire anchoring. Action of holes is taken into account by changing of bending strength. End supports were anchored stiff or hinged. Connection of treaded rods is not taken into account. ATEF is made from elastic materials. Their behaviour is described by differential equations which are solved by finite differences. As result we obtained the set of relationships "load - movement" for different start and border conditions.

Results: Obtained results allows us to range the ATEF elements by their contribution in system stiffness for choice the way to obtain desirable biomechanical characteristics. The

main contribution is made by wire stiffness. It can be controlled by changing the wire work length or pretension which is limited by elastic limit of material. The following factors are eccentricity of longitudinal load and flexibility of supporting segments: the more is diameter and the nearer a wire anchoring point to centre, the stiffer is system.

P3. Torsional strength reduction of cortical defects in femora predicted by surgeons

P D S Dijkstra¹, H M J van der Zwaag², P G H Mulder³, C J Snijders⁴, M Oudkerk⁵, T Wiggers⁶

Depts. of ¹Orthopedic Surgery, Westeinde hospital, Den Haag, ²student, University Hospital Leiden, Leiden, ³Epidemiology and Biostatistics, Erasmus University, Rotterdam, ⁴Biomedical Physics and Technology, Erasmus University, Rotterdam, ⁵Radiology, Daniel den Hoed Cancer Center, Rotterdam, ⁶Surgical Oncology, Daniel den Hoed Cancer Center, Rotterdam, The Netherlands

Thirty (orthopaedic) surgeons were asked to measure sizes and to predict torsional strength reduction on radiographs and computed tomography scans (CT) of three different cortical defects in the subtrochanteric region of the femur. These results were compared with real strength reduction measured with a torsional load test. Two femora had a transcortical defect, while one femur had partial cortical destruction. The amount of cortical destruction was most frequently mentioned by the observers as a criterion of prophylactic surgery for impending pathologic fractures. In comparison to the *in vitro* sizes the radiographic and CT scan measurements of the cortical lesions showed differences in outcome with a median of 7% and 10%, respectively. The radiographic measurement with the largest difference was the width of the cortex destruction (26%) and for the CT scan measurement this was the height of the cortex destruction (25%). Correlation between the measured outcome between radiographic and CT scan measurements held a close agreement for outer bone diameter and for the height of the defect a poor agreement. There was a significant correlation between the predicted mean torsional strength reduction in the radiographic group and CT scan group for all defects. Within a range of 20% accuracy, the percentage of observers who correctly predicted the strength reduction in the radiographic group was very low. The use of additional performed CT scans did not improve the prediction of strength reduction in the two cases with a transcortical defect.

In conclusion, this study showed that for cortical defects in the subtrochanteric region, surgeons cannot accurately measure the sizes of a cortical defect, they cannot estimate the torsional strength reduction from radiographs, and the supplementary use of CT scans does not improve these findings. Therefore, to predict the fracture risk of a metastatic lesion in the long bones, using radiographic and CT scan measurements, should be done with caution.

P4. Patient mortality after total hip replacement follow up of 35938 patients in the Norwegian Arthroplasty Register

Stein Atle Lie¹, Lars Birger Engesaeter², Leif Ivar Havelin² and Stein Emil Vollset¹

¹Division for Medical Statistics, University of Bergen,

²Department of Orthopaedics, Haukeland University Hospital, N-5021 Bergen, Norway

Patient mortality after total hip replacement (THR) was studied and compared with expected mortality for the population with the same composition of age, sex and date of birth in Norway.

Patients: In the Norwegian Arthroplasty Register we had 41,731 patients with THR, out of these 35,938 had their first primary operation registered. Patients were followed until death or till February 1, 1997. Median follow up time was 4.8 years (0–9.4), mean age was 69.1 (12–100) and 69.5% were females. 5,569 patients had a second primary operation and 2,319 revisions were registered.

Statistical methods: Survival of patients was calculated using the Kaplan-Meier method. Population mortality rates from Statistics Norway were used to calculate expected survival. Standardised mortality ratios (SMR), which is the ratio of observed number of deaths divided with the expected number of deaths in the population with the same composition of age, sex and date of birth, were also used. A Cox-model for time dependent covariates was performed to obtain the effect of multiple operations.

Results: We found a higher survival for patients with THR than expected in a similar population (Figure 1, SMR=0.81), but there was an increased mortality the first 60 days postoperatively (SMR=1.40). A higher mortality was observed for THR patients under 50 years (SMR=2.72, Figure 2). Patients with THR due to rheumatoid arthritis (SMR=1.63) and fractured femoral neck (SMR=1.13) had a higher mortality. Mortality after a revision did not differ from the mortality

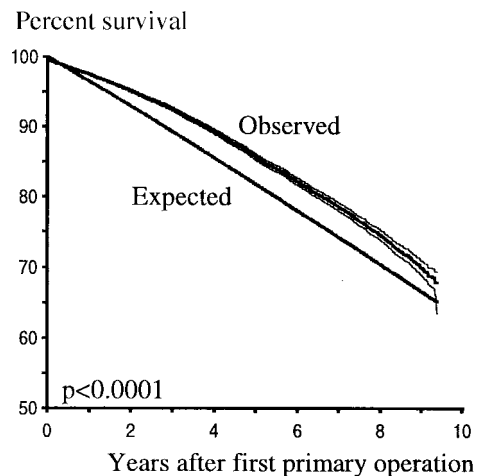


Figure 1. Overall observed and expected survival.

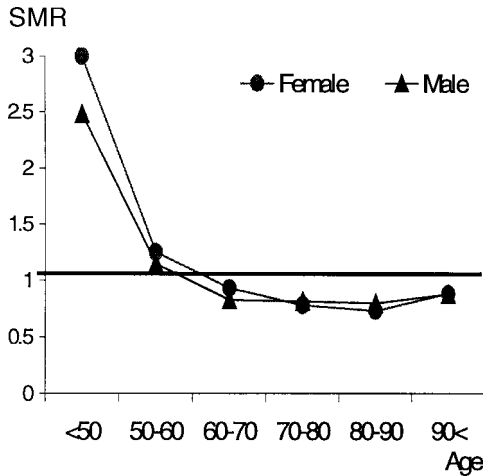


Figure 2. SMR's by age-categories and gender.

after first primary operation, but a second primary operation was associated with a lower mortality.

Conclusions: Mortality for patients with THR is lower than expected for a similar population. Young THR patients and THR patients with rheumatoid arthritis or fractured femoral neck had a higher mortality. A revision did not influence the mortality, but patients with a second primary operation had further lower mortality.

P5. Injuries associated with the use of roller-skates—do injured rollerskaters use protective equipment?

Peter Revald, Bjørn Thorup, Lars Gorm Petersen, Ole Brink

Dept. of Orthopedic Surgery, Aarhus University Hospital

Sales of roller-skates in Denmark has continuously increased of recent years. The aim was to describe the pattern of injuries associated with the use of roller-skates, and to register the use of protective equipment. The numbers of injuries related to rollerskating in 1998 is estimated.

Material and methods: From May 1996 during April 1997, total 302 patients visited the emergency unit with injuries related to rollerskating. Diagnoses, treatment, hospitalization, out patient control when required, and use of protective equipment for rollerskaters was registered.

Results: 302 patients had 353 injuries. 12 % of all injuries were localized to the head. More than 50 % of the injured patients were children younger than 15 years. Forty-five percent of the patients had fractures, and 81% were localized to the upper extremity, wrist fractures were most frequently seen. Twenty-five percent used protective equipment. Only few fractures were seen in the group of patients wearing protective equipment.

Conclusion: Preventive political strategies are needed to reduce children injuries related to roller skating, and could

include public information campaigns for wearing protective gear such as helmets and wrist, elbow and knee guards.

P6. Choice of material for plastic ligament of a knee joint

A B Slobodcoy

16 Central military specialized hospital, Shichany, Russia

Intrajoint damages of a knee joint occupy the 1 place among traumas of other joints. Thus ligament device is injured in 10–25% cases. In the literature about 250 techniques of replacement ligament of a knee joint are described. Various plastic materials are applied to it. To choose the best, for a particular patient is frequently difficult.

With a clear advantage of using autofabrics this method has a number of drawbacks. Their reserve them is limited. The capture of autotransplantation weakens stability of a joint and breaks its biomechanics. There is additional trauma. Autofabrics have not sufficient durability. Endoprosthesis ligaments from artificial fibres (alloplastic): less traumatic and is stronger. However, all drawbacks connected with strange fabric introduction in to organism, risk of teavina away is inherent in this method.

Under our supervision there were 44 patients with fresh and chronic damages of forward crosslikes and lateral ligaments of a knee joint. Age from 18 to 67, men 31, women 13. Time from the moment of a trauma to operation was from 3 days to 7 years.

In group 1 of the patients (n = 32) we applied autofabric wide fascial of a femoral (n = 21) and ligament patella (n = 11). This method was used on young, physically strong patients, with well advanced muscles–ligament device. In these cases there was an opportunity to generate strong autoligament, with the minimal trauma for the patient. Ligament from wide fascial of a hip formed by the half-closed technique, was offered by us. Patients of the senior age, especially with superfluous weight and at the majority women, have friable ligament, from them it is impossible to generate strong autoligament. Therefore in group2 (n = 12), we used lavsan endoprosthesis. The patients in postoperative period were given antibiotics for 7–10 days. Inflammation of a wound after operation was marked in 1 patient, ambassador plastics forward crosslike ligament from aponeurosis wide fascial of a hip (2.3 %). The duration of stationary treatment in group 1 was 17.4 days, in group 2, 19.9. Duration of general (common) treatment - accordingly 69.7 and 77.1 days. Good functional results are received by 28 patients in group 1 (87.5%), and by 10 patients in group2 (83.3%).

Thus, the results of treatment of ligament damages of the device of a knee joint is better, with application of autoligaments. However, choice of a material for plastic should be individual for each patient.

P7. Influence of fall characteristics on the anatomical site of hip fracture

Marty J Parker, James A Hopkinson-Wooley

Orthopaedic Department, Peterborough District Hospital, Thorpe Road, Peterborough PE3 6DA. England

Traditional orthopaedic texts state that an extracapsular fracture occurs following a sideways fall to land on the greater trochanter, whilst a twisting injury results in intracapsular fracture. This study aims to determine if this is true.

Patients and methods: 397 consecutive patients with a hip fracture were questioned with regard to the nature of their fall. 172 patients were excluded as there was no fall or they were unable to describe the exact nature of the fall. Of the remaining patients 139 sustained an intracapsular fracture and 84 an extracapsular fracture.

Results: An extracapsular fracture was more likely to result from a stationary fall and intracapsular fractures from a fall whilst walking. In addition more intracapsular fractures were associated with a fall on the affected side than extracapsular fractures. Rotation of the hip in the fall did not predispose to either an intracapsular or extracapsular fracture.

P8. Structure and properties of oxide coating applied on the orthopaedic titanium alloys by microarc oxidation

A V Karlov¹, Yu R Kolobov², L S Bushnev², E E Saguimbaev²

¹The Centre of Orthopaedics and Medical Material Sciences of SB of RAMS, and ²The Tomsk Polytechnic University, Tomsk, Russia

Bioinertness and dielectricity of the implant-organism interface has a large importance for orthopaedic implant. One of ways for this is coatings. In this communication we report results of study of structure and physical properties of bioinert TiO₂ coatings with depth 10–15 μm on Ti and its alloys Ti-5Al-2.5Sn (BT 5-1) and Ti-Al-V (BT 16) applied by microarc method in three different electrolytes, being 2.5–5% solutions H₃PO₄, KOH and oxalic acid in water.

Method: Bend and friction-on-polyethylene strength was studied by potentiostatic method for determination of electrode potential and corrosion current in physiologic solution. Coating structure was studied by microscopic and x-ray analysis methods.

Results: It was found that crystallinity of obtained coating depends on process conditions. Coatings keep good dielectric properties by bending strains about 1%. It was noted weak action of friction-on-polyethylene. Coating has closed pores about 1 μm. Microstructural analysis of element composition showed that for studied alloys additional elements content in coating is less about 1 order than in alloy. It was revealed higher contents of phosphorus when using H₃PO₄ electrolyte.

P9. Groin pain in 207 consecutive athletes—a prospective clinical approach

Per Hölmich

Clinic of Sports Medicine, Department of Orthopaedic Surgery, Amager Hospital, DK 2300 Copenhagen S, Denmark

Groin pain in athletes represents a diagnostic and therapeutic challenge. The diagnostic entities are multiple. The literature provides no consensus on the definitions and the diagnostic criteria of groin pain among athletes. Consequently, evaluation of therapeutic methods and comparison of results between studies are difficult. The aim of the present study is to categorise entities observed in athletes with groin pain based upon clinical observations.

Material and methods: 207 consecutive athletes with groin pain were prospectively examined using a standardised clinical examination program. The intraobserver and interobserver reliability of the part of the examination program regarding the adductor muscles, the iliopsoas muscle and the abdominal muscles has been validated in a separate study. The clinical entity responsible for the groin pain of each athlete was established according to a set of diagnostic criteria.

Results: Eleven athletes were female with a median range of 26 years and 196 were male with a median age of 28 years. 136 (66%) were soccer players and 37 (18%) were runners. 16 different sports accounted for the remaining 33 (16%) athletes. Adductor pain was the primary clinical entity in 58% of the patients and in 69% of the soccer players. Iliopsoas pain was the primary clinical entity in 36% of the patients and in 55% as second or third clinical entity among 69 athletes with more than one clinical entity. Rectus abdominis pain was found in 20 patients and most often considered to be secondary to adductor pain. Multiple clinical entities were found in a number of patients, 33% having two clinical entities and 8% having three clinical entities.

Conclusion: In consecutive athletes presenting with long standing groin pain the majority are soccer players among whom adductor pain is the primary clinical entity in two thirds. The present findings are difficult to compare to those of previous studies due to the lack of uniform generally accepted diagnostic criteria, previously employed.

P10. Clinical examination of athletes with groin pain—an intraobserver and interobserver reliability study

P Hölmich, A M Bjerg, L R Hölmich

Clinic of Sports Medicine, Department of Orthopaedic Surgery, Amager Hospital, and Copenhagen Trial Unit, Institute of Preventive Medicine, H:S Kommunehospital. Copenhagen, Denmark

The literature provides no consensus on the definitions and the diagnostic criteria of groin pain among athletes. To establish diagnostic entities and to compare results of different

studies the use of identical and well documented methods are essential. The aim of the present study was to evaluate different clinical examination techniques for athletes with groin pain.

Methods: 18 athletes, 9 with groin pain and 9 without groin pain, were examined by 2 physicians and 2 physiotherapists. The examination technique was trained before the study. The examination was done blinded by the observer. All examiners tested the patients twice in a random order. The tests included: adductor related pain and strength, iliopsoas related pain, strength and flexibility, abdominal pain and strength and pain at palpation of the symphysis joint.

Results: Kappa statistics were used to analyse the observations. The 4 observers were compared in pairs and among themselves. With a few exemptions the tests showed "very good" or "good" agreement according to the definitions by Altman (1992). The examination techniques and the detailed results of the statistical analysis will be presented.

P 11. Ileopectineal bursa distension with fixed uncemented prosthesis

Lars Nordsletten and Stein Øvre

Orthopaedic department, Ullevål University Hospital, Oslo, Norway

Wear of total hip replacements (THR) leading to osteolysis is well described [1], while high fluid production with communication to the ileopectineal bursa is a rarely reported complication [2]. Patients presenting with distal or local phenomena due to distension of the ileopectineal bursa with fixed uncemented prosthesis is presented.

Material: Six patients (one man) operated with uncemented THR (age 42-62 years) were referred for local swelling and pain in the affected hip (n=1) or swelling of the lower leg (n=5). Before being referred they had undergone phlebography (n=5), ultrasound/Doppler (n=5), cytology (n=6), CT (n=5) and scintigraphy (n=2).

Results: On referral all patients had fixed uncemented prosthesis (Biomet European/Jensen Cup, Taperlock femur [n=5], Harris Galante cup/stem [n=1]) with excessive wear of the liner and additional osteolysis. Time from primary operation to referral were median 6.3 (4-10) years. The cysts were aspirated for 30-50 ml fluid with symptom relief prior to revision, some patients needed repeated aspiration. The patients have been reoperated after median 6 (2.9-34) months from symptom debut. At the time of revision three

were painfree in the hip. In three patients the whole prosthesis was revised, in one the femoral stem and the liner were exchanged, and in two only the cup and modular head were exchanged. All symptoms connected to the distended bursa have been relieved, and ultrasound have not identified it after revision. Cytology have shown macrophages with prosthetic particles of the same type as found in the joint during revision.

Discussion: In 14% of normal hip joints there is a communication to the ileopectineal bursa [4]. Wear and particle production may lead to high fluid pressure [3] and with a one way valve mechanism the bursa will be distended and painful, and may externally compress the femoral vein. These patients should be revised promptly as repeat aspiration is necessary if they have to wait, as in all of our patients.

References: 1. Nordsletten, L., *et al. Acta Orthop Scand* 1996; 67 (Suppl 270): 3-4.

2. Goyal, S., *et al. Acta Orthop Scand* 1997; 68: 67-9.

3. Robertson, O., *et al. Acta Orthop Scand* 1997; 68: 231-4.

4. Chandler, S.B. *Anat Rec* 1934; 50, 235.

P12. The Exeter stem subsides within the cement both in primary arthroplasties and in revisions using morzelised allografts

Ewald Ornstein¹, Herbert Franzén², Ragnar Johnsson³, Thomas Löfqvist¹, Anna Stefánsdóttir¹, Martin Sundberg¹

Departments of Orthopedics, ¹Hässleholm-Kristianstad Hospital, S-281 25 Hässleholm, ²Ängelholm County Hospital, S-262 81 Ängelholm and ³Lund University Hospital, S-221 85 Lund, Sweden.

Purpose: To evaluate whether the Exeter stem subsides at the stem-cement or/and the cement-femoral bone interface and if there is any difference between primary and revision arthroplasties.

Patients and methods: Subsidence of the stem was analysed with RSA in 2 primary (P) cemented arthroplasties and 3 revisions (R) with morselized allografts and cement.

Results: All five stems subsided within the cement. In 2 revisions there was additional subsidence of the cement relative the femur (Table).

Conclusions: The major part of the stem subsidence occurred within the cement, however in two revisions a slight movement of the cement occurred. Longer follow-up will show whether the subsidence continues and leads to clinical failure.

Table

Case	Stem versus cement (mm)				Stem versus femur				Cement versus femur			
	6 w	3 m	6 m	1 y	6 w	3 m	6 m	1 y	6 w	3m	6 m	1 y
P 1	0.7	1.1	1.5	1.8	0.7	1.0	1.4	1.7	0	0	0	0
P 2	0.7	0.9	0.9	1.0	0.7	0.9	0.9	1.1	0	0	0	0
R 3	0.7	1.0	1.5	-	0.8	1.1	1.5	1.9	0	0	0	-
R 4	1.5	1.7	1.8	1.9	1.3	1.7	1.9	2.2	0.3	0.4	0.5	0.5
R 5	1.3	1.9	2.3	2.7	1.7	2.6	3.0	3.3	0	0	0	0.3

P13. Low serum albumin on admission is associated with a high mortality rate but not with deep wound infections in patients with femoral neck fractures.

Margareta Hedström¹, Lollo Gröndal¹, Åke Örtquist², Nils Dalén¹ and Torbjörn Ahl¹

Karolinska Institute, Depts. of ¹Orthopedics and ²Infectious Diseases, Danderyd Hospital, S-182 88 Danderyd, Sweden.

The aim of the study was to determine the incidence of deep wound infections after surgery of femoral neck fractures and to identify variables that might affect the rate of infection. We also wanted to study the mortality in this group of patients and the nutritional and clinical factors that could be of importance for a poor prognosis.

Patients and methods: 437 patients with femoral neck fractures were included in the study. They were operated on with closed reduction and internal fixation with two cancellous bone screws. Prophylactic antibiotics were not used. The patients hospital records were studied regarding variables that might affect the infection and mortality rate.

Results: 3% of the patients developed a deep infection. The only factors associated with deep wound infection were operating time and male sex. The mortality rate was 24% during the first year. Age, male sex, senile dementia and low admission levels of serum albumin were independently associated with a higher one year mortality rate.

Conclusion: The deep wound infection rate was low, indicating that general antibiotic prophylaxis need not be recommended for femoral neck fractures. Serum albumin on admission can not be used as a predictor for postoperative deep wound infection, but is an indicator for high mortality rate and can identify patients who might benefit from nutritional support.

P14. Preliminary results after transpedicular BMP-7 transplantation in unstable spine fractures

Malene Laursen, Christian Høy, John Gelineck, Ebbe Stender Hansen, Finn Bjarke Christensen, Søren Eiskjær and Cody Bünger

Spine Unit, Department of Orthopedics E, University Hospital of Aarhus, Denmark

Recombinant human BMP-7 in combination with a collagen carrier have shown to promote posterolateral spine fusion and to restore segmental bone defects in animal studies and has been approved for clinical use by the Danish National Board on Health.

The aim of this pilot-study was to investigate the clinical outcome after transpedicular intracorporeal BMP-7 application in thoracolumbar burst fractures.

Patients and methods: Four patients with unstable fracture of the thoracolumbar spine and no neurological impair-

ment were treated with transpedicular BMP-7 transplantation, posterior internal fixation (USS) and posterolateral fusion. One patient with osteoporosis had additional intracorporeal transplantation performed proximal to the instrumented segment, i.e. BMP into Th12 and bone into Th11.

Results: In one case, radiographic and CT evaluation after three and six months showed severe bone resorption at the transplantation site and in a second case loss of anterior column height and kyphotic correction were observed at three months follow-up. No change in bone density was seen proximal to the instrumented vertebrae in the patient with osteoporosis after four months. Despite the poor radiological outcome, the patients are without complaints and two are back to previous levels of employment.

Conclusion: In the present study, results regarding BMP-7 as a bone graft substitute have been disappointing but no definite conclusions can be made from these few and preliminary results. Yet there are indications to suggest that BMP-stimulation of bone healing in humans primarily results in enhanced bone resorption.

P15. Adjustment of external fixators stiffness to ensure optimal healing of long bones fractures

Anatoly V Karlov¹, Vladimir N Likhachov²

¹Centre Orthopaedics and Medical Material Sciences of SB of RAMS, and ²Clinical Scientific Production Association "Biotechnika", Tomsk, Russia

Choice of stiffness of different schemes of as-telescopic external fixators assembling in dependence on support element geometry to ensure optimal healing of long bones fractures in dependence on their type is considered in this work.

Methods: To solve this problem and to choose a stiffness regime the test bench for quantitative measurement of bone tissue destruction in dependence on fracture type according Müller (1993) classification was constructed. It was found that less hard fractures require fixators assembling with less quantity of additional elements. With increase of destruction energy it requires increase of the fracture fixation stiffness, decrease of support element length along extremity contour and introducing additional vertical threaded connecting elements in form of two equilateral triangles.

Conclusion: Results of this work were used for treatment of 119 patients with different bone fractures, 59 of them were treated before by Ilizarov's apparatus. All the patients were healed in terms, which correspond to fracture type. Thus adjustment of as-telescopic fixators stiffness according to fracture type allows to solve any clinic tasks.

P16. Optimal configuration and optimal bio-mechanics of the as telescopic external fixators

A V Karlov¹ and V N Lichachov²

¹Centre Orthopaedics and Medical Material Sciences of SB of RAMS, and ²Clinical Scientific Production Association "Biotechnika", Tomsk, Russia

The stress-strain states of single elements of as-telescopic external fixators (ATEF) in which centres of supporting elements with different sizes is along one line coinciding with extremity axis and choice of supporting element configuration corresponding to fracture heaviness and concrete struck extremity segment is considered in this work

Method: In this work the ATEF supporting elements are assembled as any geometric figure that is divided on three equal parts with holes on every part of supporting elements being on equal distance each to other and line passing through their centres forms angle being between 60° and 180°. Configuration of elements for mounting of above construction was determined with calculation algorithm based on theory of beams and threads.

Results: The results allow to develop algorithm for obtaining of ATEF biomechanical characteristics being optimal for treatment of concrete fracture and for choice of supporting element. This algorithm was used for treatment about 200 patients with long bone fractures and 98% of them were healed in optimal time for every fracture type.

P17. Progress in physical activity after knee arthroplasty measured electronically by means of a three-direction accelerometer.

L P Jornt¹, S Toksvig-Larsen¹, M Werner², G Andersson³ and A Lindstrand¹

Depts. of ¹Orthopedics, ²Anaesthesiology and ³Neurophysiology, Lund University Hospital, Sweden

To assess the progress in the early mobilisation after knee prosthetic surgery we studied a three-directional accelerometer—the Motionlogger™ Actigraph in a clinical study. The Actigraph can translate body movement into an electric signal and interfaces with a microcomputer for downloading the data. Earlier studies with this Actigraph—the size of a wrist watch—have shown a high reproducibility and correlation between registered activity and the intensity at different physical workloads^{1,2}. It has, however, not been applied in orthopaedic surgery.

Patients and method: 25 patients, age 73 (64–83), scheduled for unilateral knee prosthetic surgery because of knee arthrosis wore a Motionlogger™ Actigraph fastened to the leg and worn continuously from 5 days before surgery to 12 days postoperatively. This even included registration at home after the departure. A further registration for 6 days was included 4 months postoperative by mailing the Actigraph to the patients. We expressed the postoperative daily activity for each patient in percent of the individual median

daily preoperative activity.

Results: All patients tolerated the registration and the data transmission was uncomplicated and without loss of data. The in-hospital time was 7 (4–9) days. Immediately postoperative the activity was reduced to 20% ±10%, and gradually increased to 75% ±15% during the first week. The activity at departure was 60% ±14% and did not change significant during the first days at home. At the 4-month control activity was 106% ±26%.

Conclusion: Actigraph measurement proved capable of a continuing activity registration in a clinical setting. The method is not observer dependent, can be extended to registration after the departure, and extends our knowledge of the newly operated patient's level of rehabilitation.

References: 1. Pattersson S M, Krantz D S, Montgomery L C et al: Automated physical activity monitoring: Validation and comparison with physiological and self-report measures. *Psychophysiology*, 30(1993), 296-305.

2. Sugimoto A, Hara Y, Findley T W et al: A useful method for measuring daily physical activity by a three-direction monitor. *Scand J Rehab Med* 29:37-42.

P18. Reconstruction of the hip after pathological fracture of the acetabulum

Henrik C F Bauer and André Stark

Oncology Service, Department of Orthopedics, Karolinska Hospital, S-104 01 Stockholm, Sweden. Tel +46-8-51772671. Fax +46-8-51774699. e-mail bauer@ort.ks.se.

Cement and pins have been used to augment the acetabulum in hip replacement for pathological fracture. We report our results using reinforcement rings.

Patients and methods: 23 cancer patients were operated because of pathological fracture of the acetabulum. There were 11 men and 12 women and the median age was 65 (40–84) years. The site of the primary tumor was the breast in 9 cases, the prostate in 4, and other sites in 10. All patients were operated through a postero-lateral approach by resection of the affected hip joint and curettage of the acetabular defect. Reconstruction was performed by the use of a screw-fixed reinforcement ring, cement, and a Charnley or MS30 prosthesis. The median operation time was 150 (90–215) minutes and the perioperative bleeding was 1300 (420–9000) ml.

Results: 2 patients died within 2 weeks of surgery in circulatory failure. Dislocation of the prosthesis occurred in 6 patients, none necessitating revision. There was only 1 dislocation among the 13 patients operated since 1995. The median 1-year survival was 50%. Early failures, with loosening of the reconstruction, was seen in 2 patients. The remaining patients were able to return to full pain-free weight bearing with no further surgery.

Conclusions: Reconstruction of the hip is often possible even in severe destruction of the acetabulum. The survival was considerably better compared to our series of patients with pathological fracture of long bones. Patients with ace-

tabular fracture can be more carefully selected than patients with extremity fractures who require emergency surgery.

P19. Impacted cancellous bone grafting and recementing of loose components in rigid hinged knee arthroplasty

Poul Torben Nielsen and Christian Pedersen

Dept. of Orthopedic Surgery, Aalborg Hospital, Denmark

Rigid hinged knee prostheses were used in the early years of knee arthroplasty, primarily in the seventies, but since then surpassed by total condylar designs. They failed due to their inability to distribute rotational stress around the knee, resulting in aseptic loosening, high infection rates (5–10%), periprosthetic fractures (2–4%) and patellar problems (10–15%).

Revision of hinged prosthesis implies a high rate of fracture due to osteolysis (30%), high rates of infection (4–20%) and poor clinical results. Arthrodesis after failed hinged prostheses has failure rates of 50%.

We have used a hitherto not published revision procedure in four patients with loose hinged prosthesis.

Material and methods: Four patients with 11–15 years old rigid hinged knee prostheses were revised because of aseptic loosening and severe osteolysis with imminent risk of periprosthetic fracture. The main clinical feature was pain. The average Knee Society scores were 43, and the function score 32 points.

At surgery the hinge was separated, the loose component removed and cleaned, osteolytic bone was curetted, morsellized autograft bone was impacted and the component recemented before the hinged was reassembled. The patients were braced for 6 weeks before starting weight-bearing.

Results: At follow-up 6–30 months after operation the Knee Society scores had increased to 83 points on average and the function score to 53 points. The patients were pain free and had only slight pain occasionally. Radiographs of one of the femoral components showed initial subsidence, but no further signs of loosening.

Discussion: Impacted cancellous bone grafting and recementing is a new procedure in salvage of loose hinged knee arthroplasty components. The short term clinical results were good in these elderly patients with low activity level. It may prove to be a lasting solution and a good alternative to arthrodesis or amputation.

P20. BMD measured by DEXA of the distal femur following uncemented TKA

Michael M Petersen¹, P Martin Gehrchen¹, Henrik M Schröder¹, Palle K Nielsen², and Bjarne Lund¹

Depts. of Orthopedics¹ and Nephrology², Rigshospitalet, Copenhagen, Denmark

Studies using finite element analysis have suggested that fol-

lowing total knee arthroplasty (TKA) stress shielding leading to the development of bone loss is expected to occur in the anterior distal femur (1,2). Recently measurements of bone mineral density (BMD) have shown a decrease in BMD of approximately 40% 6 months after TKA (3).

Materials and methods: 8 patients (F/M=7/1, age 74 (66–82) years) with osteoarthritis of the knee operated on with insertion of uncemented TKA (Interax™ total knee system, Howmedica®) using femoral components with a cast-mesh ingrowth surface without hydroxyapatite coatings were included in the study. Measurements of BMD were performed by dual energy X-ray absorptiometry (DEXA) using the Norland XR-26 Mark II scanner. Scannings (scan speed 45 mm/s, pixel size 0.5 x 0.5 mm) were performed in the medio-lateral plane of the distal femur above the femoral component postoperatively and at follow-up after 3 and 6 months. 4 regions of interest were selected for measurements of BMD (g/cm²); 3 regions located at the level above the fixation peg and 1 region below behind the peg.

Results: The prospective changes in BMD showed significant changes (p<0.05) only in the distal region behind the fixation peg where BMD had decreased by 10% and 5% after respectively 3 and 6 months.

Discussion: BMD decreased only in the distal region. The early adaptive bone remodeling pattern for this new femoral component did seem to be very beneficial and different from the femoral components previously examined (3,4).

References: 1. Walker et al. Eng Med. 1982; 11: 135-40.
2. Tissakht et al. J Orthop Res. 1996; 14: 778-85.
3. Petersen et al. Acta Orthop Scand. 1996; 67: 339-44.
4. Liu T-K et al. Int Orthop. 1995; 19: 346-51.

P21. Quantification of bone mineral density after spinal fusion in rabbits with autogenous-versus xenogenous bone transplant covered with a collagen membrane

P Martin Gehrchen, Michael Nielsen, Lars Nimb, Jørgen Holm, Palle K Nielsen and Thomas Kiar

Dept. Of Orthopaedic surgery, Spine section, Rigshospitalet, University of Copenhagen, DK

Quantification of bone mineral density (BMD) after spinal fusion was performed in two series of fusions using either xenogenous bone transplant (Bio-Oss) covered with a collagen membrane (Bio-Gide) or autogenous bone transplant. Bio-Gide is a bilayer collagen membrane; one compact and smooth layer designed to prevent invasion of soft tissue, and the other rough side, is designed to make bone ingrowth possible. Bio-Oss is a bovine deorganified crystalline bone matrix.

Materials and methods: Twelve rabbits had a posterior lumbar fusion at one segment using either autogenous bone transplant (group A, n=8) or Bio-Oss covered with Bio-Gide (group B, n=4). All animals were killed after 5 weeks and the spine was removed en bloc. BMD was measured using Dual Energy X-ray Absorptiometry in two regions of interests

(ROI's). ROI 1, at the level above the fusion and ROI 2 at the fusion level. For the statistical analyses one- and two sample t-test for parametric data were used.

Results: See figure. The BMD was significantly higher for Bio-Oss/Bio-Gide compared to autogenous transplant when comparing the two series (** $p=0.00002$) and the two levels in the same animal (* $p=0.005$).

Conclusion: It is possible to quantitate differences in BMD using DEXA after fusion in the rabbit spine operated on with different types of bone transplantation. Bio-Oss/Bio-Gide seems to result in higher BMD values at the fusion site after 5 weeks compared to autogenous bone transplant.

Reference: 1. Schlegel AK, Mohler H, Busch F, Mehl A: Preclinical and clinical studies of a collagen membrane (Bio-Gide). *Biomaterials* 1997; 18: 535.

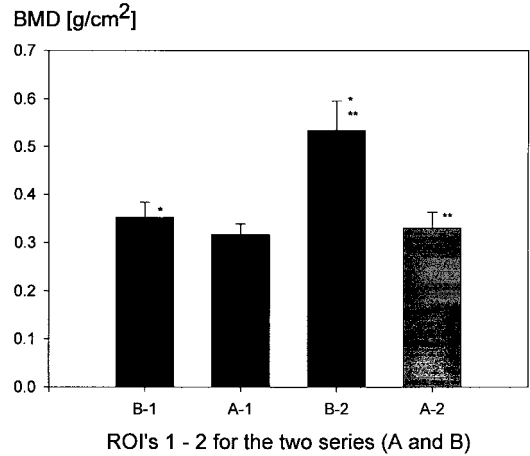


Figure. Bone mineral density, BioOs + BioGide versus autogenous bone transplant.